



**EMIRATES SOCIETY
OF COLON & RECTAL SURGERY**
جمعية الإمارات لجراحة القولون والمستقيم

ميدىكلينيك
MEDICLINIC


TATME THE BOTTOM-UP APPROACH

Dr Sara Al Bastaki

Consultant Colorectal Surgeon

Consultant Colorectal Surgeon mediclinic City & Airport Road Hospitals

President of Emirates Society of Colon & Rectal Surgery





OBJECTIVES

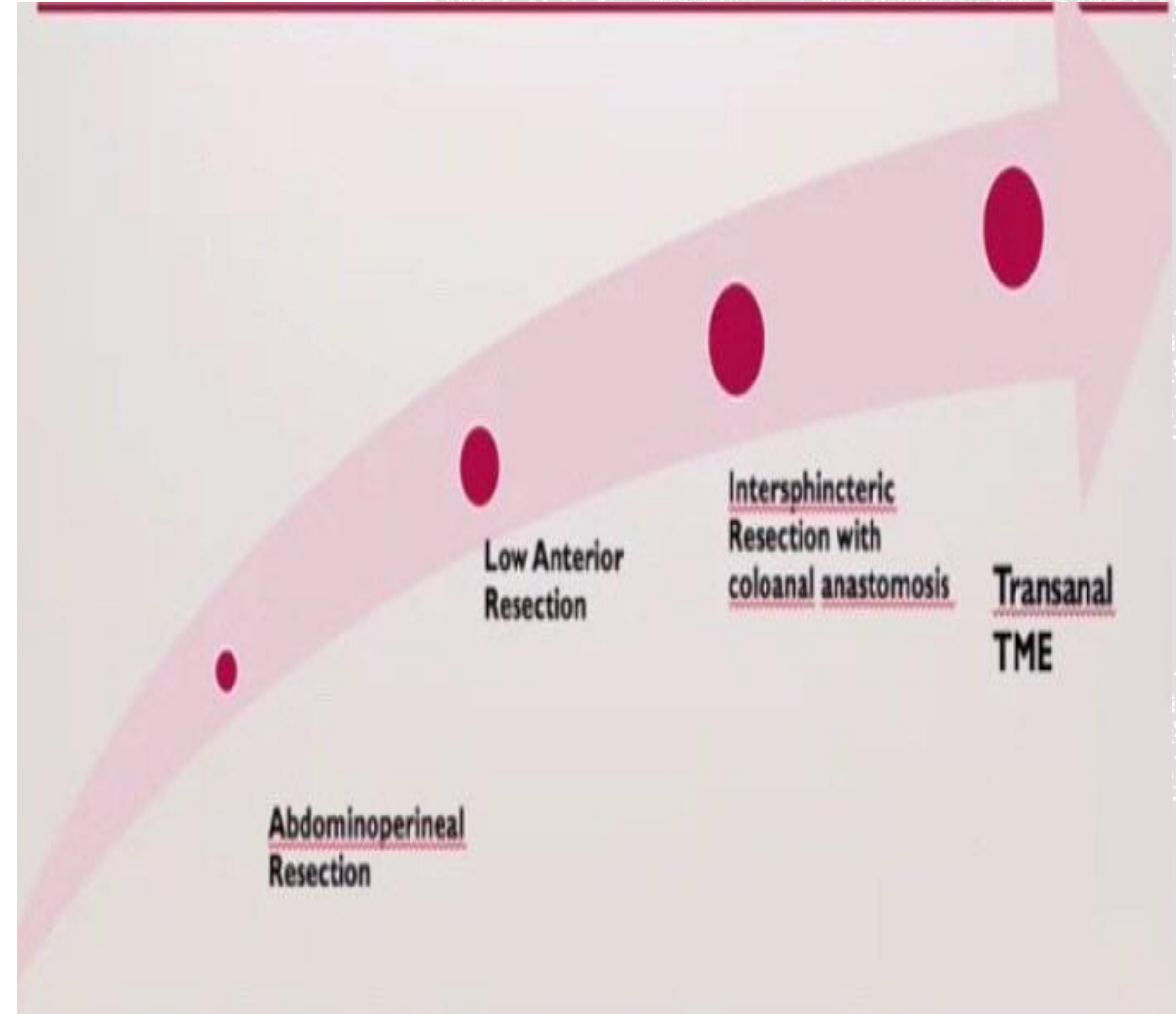
- Learning new techniques
- Challenges of low Rectal cancer
- Benefits of low anastomosis
- Which layer of dissection and the extension?
- TATME outcomes



INTRODUCTION

Over the past two decades, rectal cancer management underwent huge wave of changes:

- A worldwide application of neo-adjuvant multimodal CRT for local advanced stage disease.
- A smart shift from open to minimal invasive techniques.





TME COULD BE COMPLETED VIA

- An open anterior abdominal approach.
- Laparoscopic TME
- Robotic TME
- Recently, transanal TME (TaTME).





EMIRATES SOCIETY
OF COLON & RECTAL SURGERY
جمعية الإمارات لجراحة القولون والمستقيم

RISK FACTORS FOR POOR QUALITY TME

- Male gender
- High body mass index (BMI > 30)
- Visceral obesity
- Narrow pelvis
- Bulky tumors
- Advanced T stage



Technical challenges during both open & laparoscopic surgeries

- Poor exposure of mesorectal plane.
- Difficult in introducing instruments in narrow space with fixed bony pelvis.
- Subsequently can lead to inaccurate dissection and uncertain margins.



EVOLUTION OF TATME

TaTME has been inspired from a combination of other techniques:

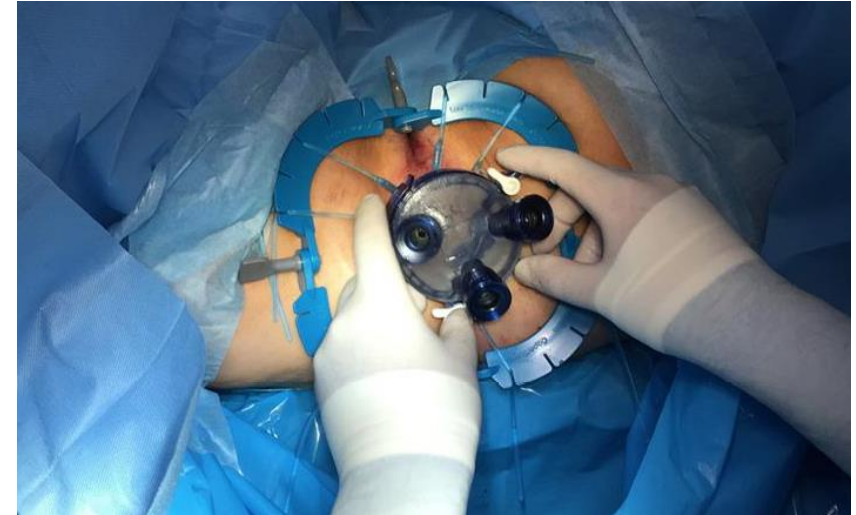
- Transanal endoscopic microsurgery (TEM)
- Transanal transabdominal approach (TATA)
- Natural orifice transluminal endoscopic surgery (NOTES)
- Transanal minimally invasive surgery (TAMIS)



WHAT DOES TATME OFFER?

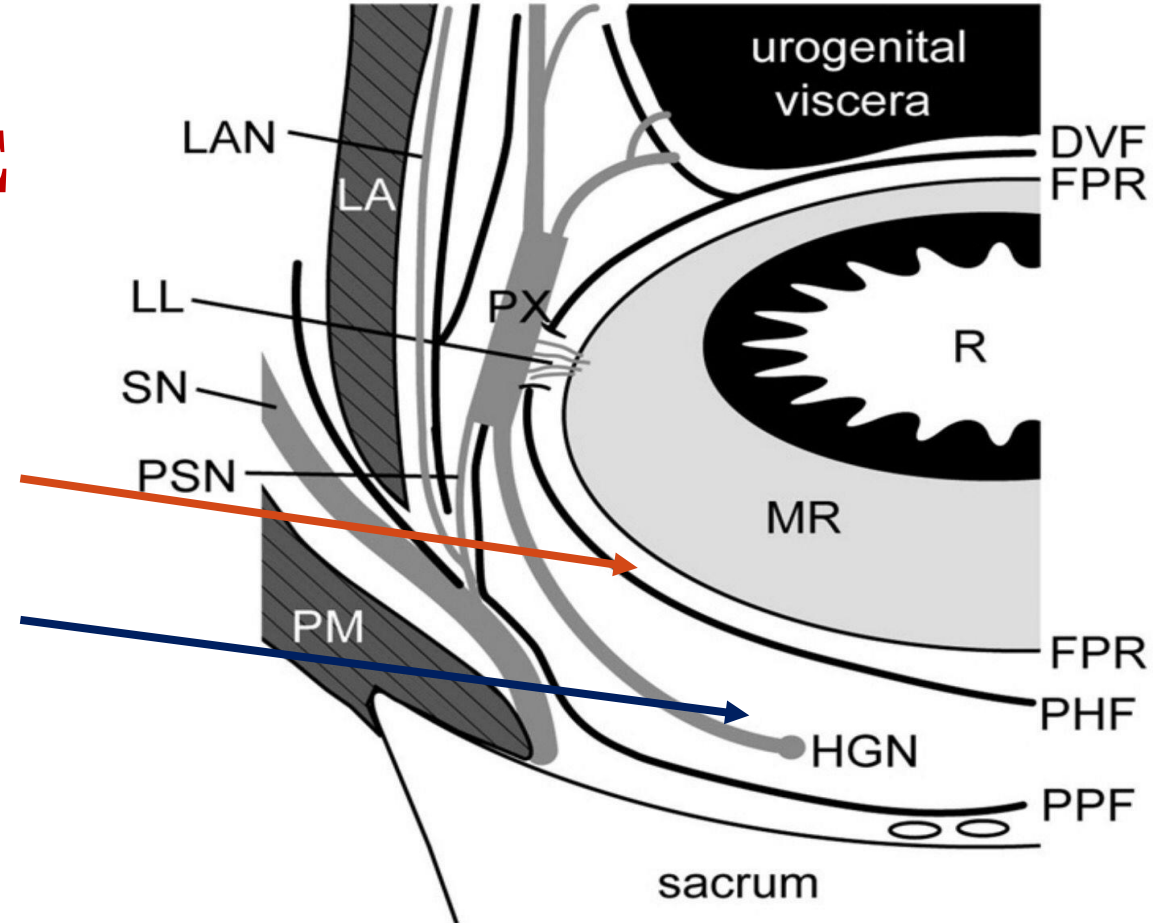
“**Bottom-up**” approach offers:

- Clearer visualization of the dissection plane
- Preserving the pelvic autonomic nerves with potentially improved bowel, urinary and sexual functions.
- Avoiding excessive manipulation of the specimen to obtain exposure, thus allowing a more precise and trauma-free dissection.
- Better determination of the distal margin.
- Better stapling technique, avoiding dog ear and restriction of angulation of stapler.



TME

- Two surgical dissection planes are possible posterior and lateral to the rectum:
 1. Between the fascia propria of the rectum and the prehypogastric nerve fascia.
 2. Between the prehypogastric nerve fascia and the parietal pelvic fascia.
- The first dissection plane is better to avoid nerve damage.
- A dissection plane behind the parietal pelvic fascia causes injuries not only to the pelvic plexus, but also to the levator ani nerves.

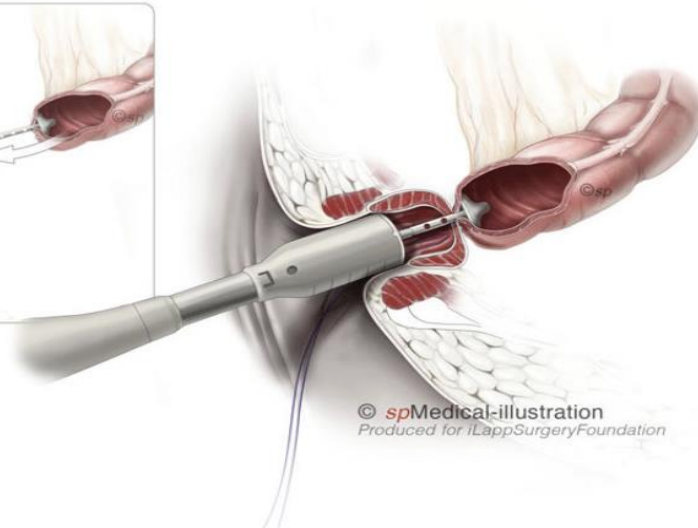
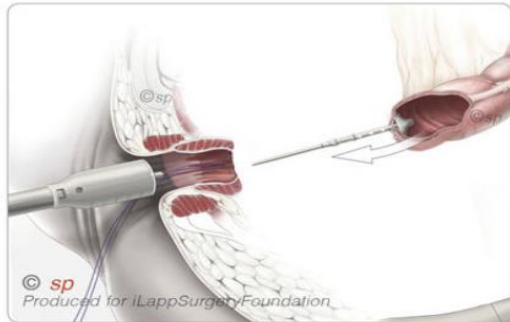
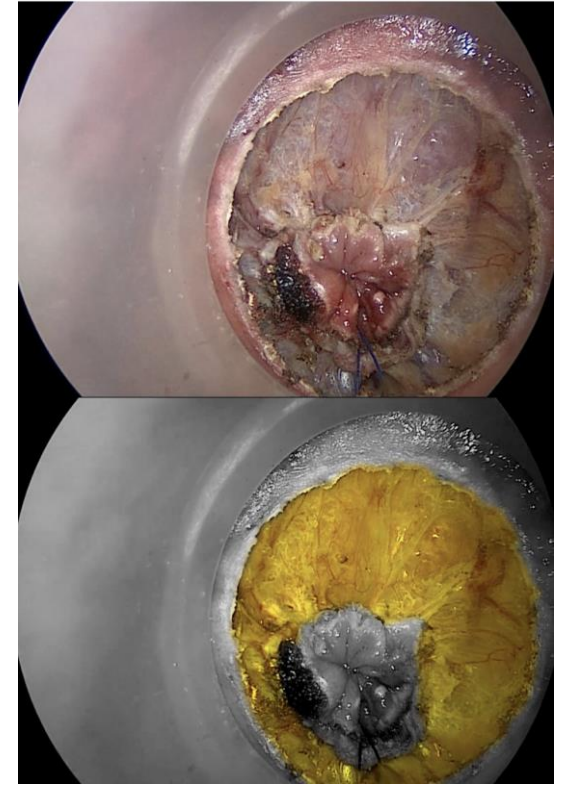
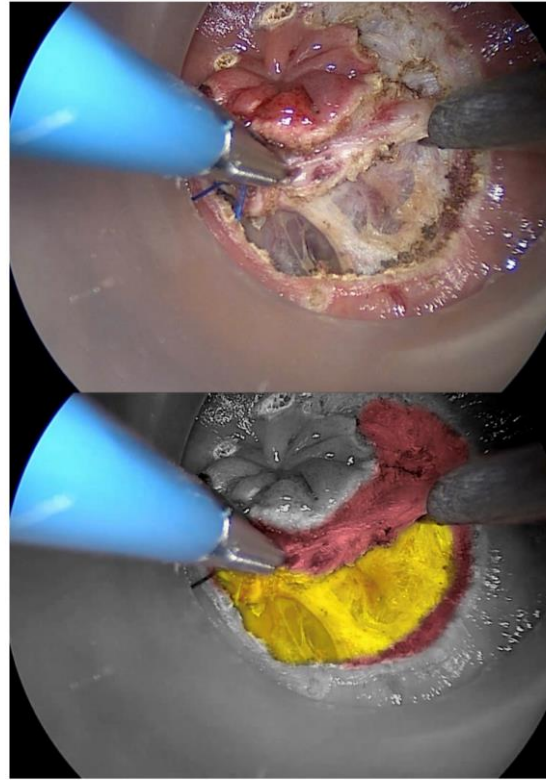
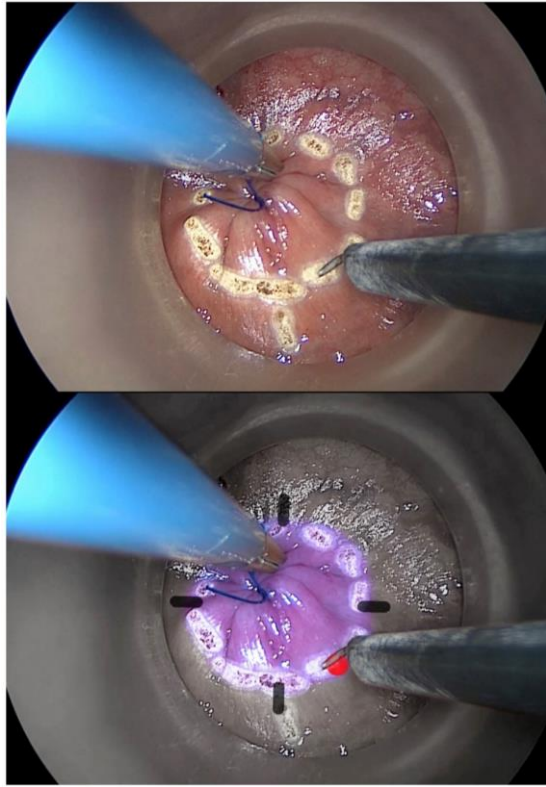
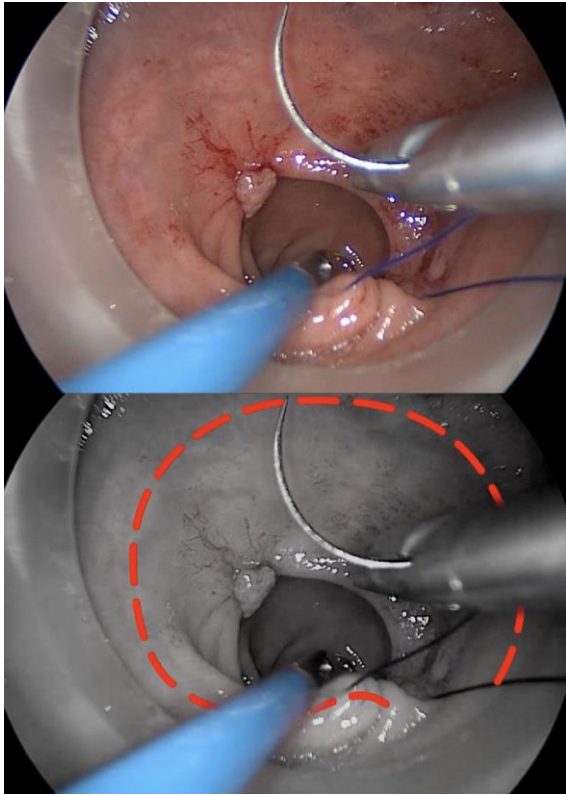


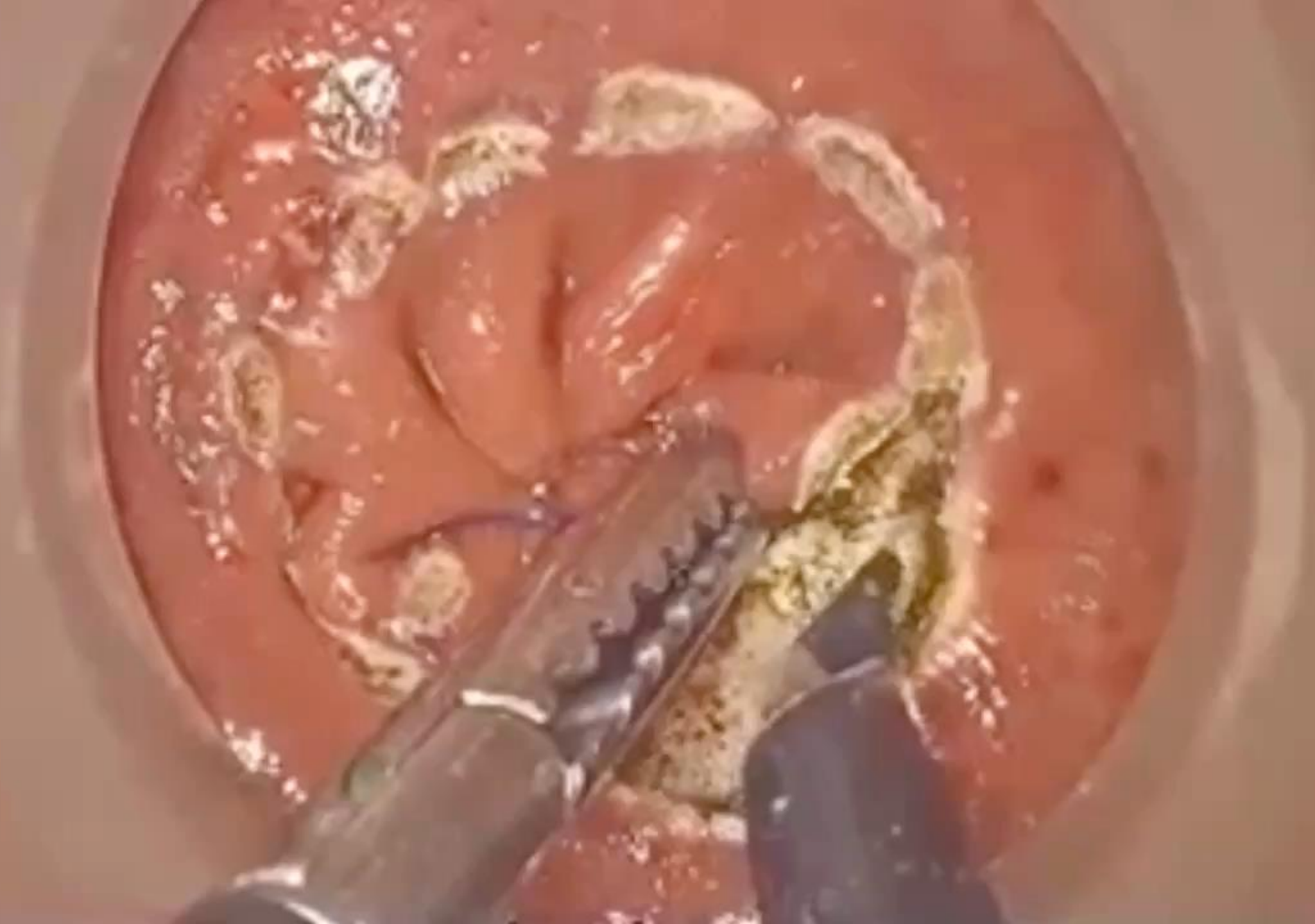■ Schematic representation of fasciae around the rectum (horizontal). DVF, Denonvilliers' fascia; FPR, fascia propria of rectum; HGN, hypogastric nerves; LA, levator ani muscle; LAN, levator ani nerve; LL, lateral ligament; MR, mesorectum; PHF, prehypogastric nerve fascia; PM, piriformis muscle; PPF, parietal pelvic fascia; PSN, pelvic splanchnic nerves; PX, pelvic plexus; R, rectum; SN, sacral nerve.

TECHNIQUE

- Completion of abdominal part (open/laparoscopic/Robotic).
- Positioning of lone Starr retractor.
- Identification of dentate line and safe distal margin.
- Rectal lumen closure with purse string, mucosa marked with cautery outside the fold of the purse string in a circle fashion.
- Full thickness transection of rectal wall after Gelpoint insertion. Find FPR
- Down to Up dissection through TME plane (5 and 7 o'clock posteriorly, 1 and 11 o'clock anteriorly). CAVE: NVB
- Specimen extracted trans-anally, transection using linear stapler , Anvil inserted and secured with purse string (1).
- Another purse string (2) done in distal rectal cuff.
- Circular stapler : End to side anastomosis.







BENEFITS OF DISTAL ANASTOMOSIS IN TATME

Results:

- LR in DRM<1 cm (6.1%) and DRM≥1 cm (5.5%).
- 5-year LRFS was 93.2% in DRM<1 cm and 95.7% in DRM ≥1 cm

Conclusion:

- R0 resection of stage II and II rectal cancer of the mid and lower third after preoperative CRT yields excellent results even with DRM<1 cm.
- Minimizing the distal resection margin may allow surgeons to offer sphincter sparing surgery without compromising local recurrence-free and overall survival in individual patient.

Original Research

The minimum distal resection margin in rectal cancer surgery and its impact on local recurrence - A retrospective cohort analysis



2019

Philipp Manegold*, Johannes Taukert, Hannes Neeff, Stefan Fichtner-Feigl, Oliver Thomusch

University Medical Center Freiburg, Department of General and Visceral Surgery, Hugstetter Straße 55, 79106, Freiburg, Germany





Single-stapled double-pursestring anastomosis after anterior resection of the rectum

Slawomir J. Marecik, M.D.^{a,b}, Vivek Chaudhry, M.D.^a, Russell Pearl, M.D.^a,
John J. Park, M.D.^{a,b}, Leela M. Prasad, M.D.^{a,b,*}

^a*Cook County Colon and Rectal Surgery Residency Training Program, Chicago, IL, USA*

^b*Department of Surgery, Advocate Lutheran General Hospital, 1775 W. Dempster St., 8 South, Park Ridge, IL 60068, USA*

Presented at the 49th Annual Meeting of the Midwest Surgical Association, Mackinac Island, MI, August 6–9, 2006

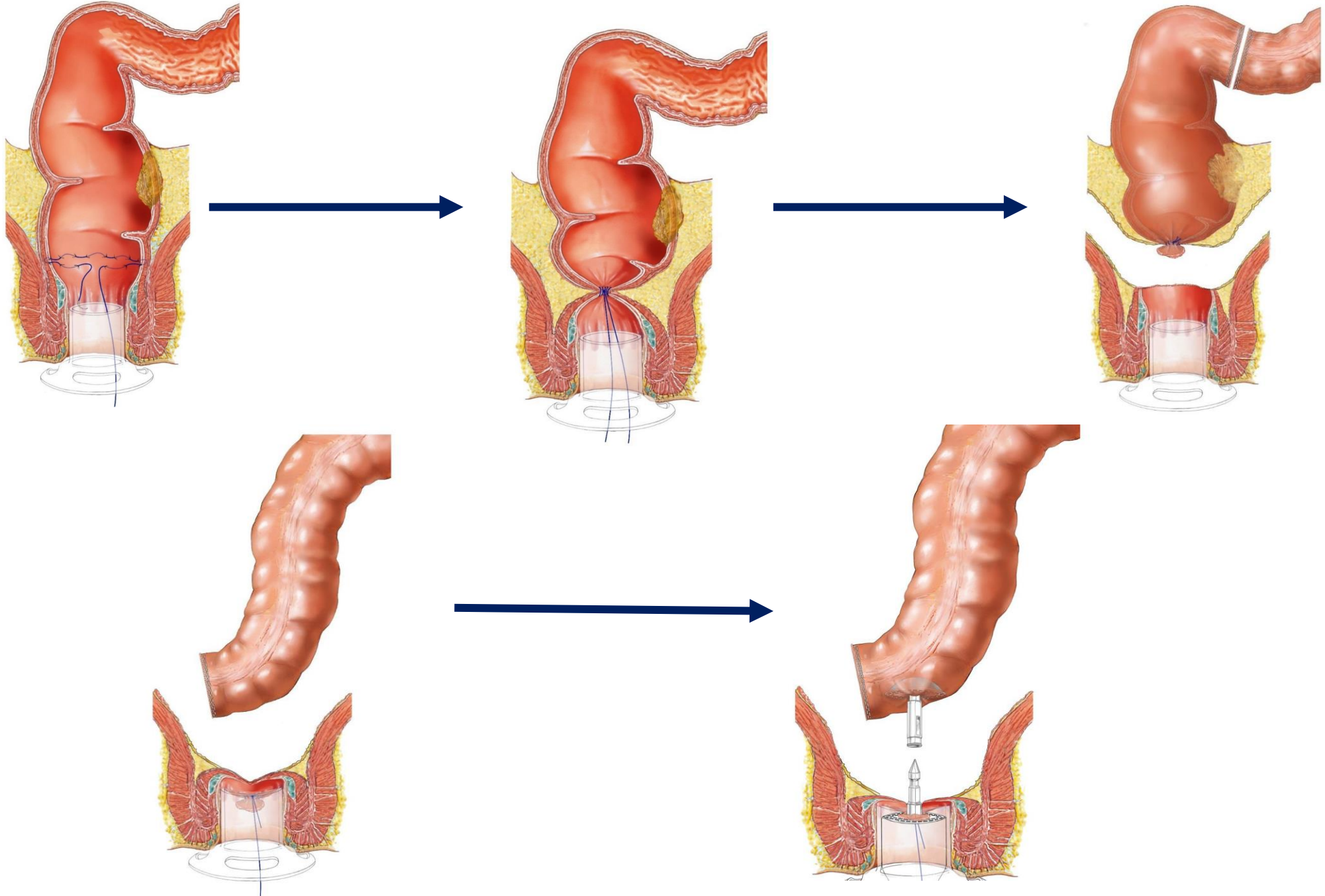
Conclusion

Single-stapled double-purse string anastomosis is reliable, with very low rates of leak, subsequent diversion, and pelvic abscess (.6%, .6%, and 2.5% respectively).





EMIRATES SOCIETY
OF COLON & RECTAL SURGERY
جمعية الإمارات لجراحة القولون والمستقيم





Outcome TATME

- Better oncological resections
- Reducing the need for APR & definitive colostomy

TATME potentially generates a new surgical approach option, especially in cases with very low tumors, obese patients and narrow pelvis





EMIRATES SOCIETY
OF COLON & RECTAL SURGERY
جمعية الإمارات لجراحة القولون والمستقيم

Surgical Endoscopy

<https://doi.org/10.1007/s00464-017-5990-2>

ميدىكلينىك
MEDICLINIC



CONSENSUS STATEMENT



St.Gallen consensus on safe implementation of transanal total mesorectal excision

Michel Adamina^{1,2}  · Nicolas C. Buchs³ · Marta Penna⁴ · Roel Hompes⁵ · on behalf of the St.Gallen Colorectal Consensus Expert Group 2017

Conclusion

Multidisciplinary consensus statement achieved more than 80% approval and can thus be graded as strong recommendation. It provides the best possible guidance for safe implementation and practice of Transanal Total Mesorectal Excision.





EMIRATES SOCIETY
OF COLON & RECTAL SURGERY
جمعية الإمارات لجراحة القولون والمستقيم

ميدىكلينىك
MEDICLINIC

Techniques in Coloproctology

<https://doi.org/10.1007/s10151-018-1844-8>

CHALLENGES IN COLOPROCTOLOGY



Transanal total mesorectal excision for rectal cancer: state of the art

David A. Westwood¹ · Tahleesa J. Cuda¹ · A. E. Ricardo Hamilton¹ · David Clark^{1,2} · Andrew R. L. Stevenson^{1,2}

Received: 26 November 2017 / Accepted: 1 September 2018

© Springer Nature Switzerland AG 2018

Conclusion

Preliminary outcome data suggest that TATME is oncologically safe, resulting in low positive margin rates and good specimen quality with acceptable short-term patient outcomes



REVIEW



Meta-analysis of transanal total mesorectal excision versus laparoscopic total mesorectal excision in management of rectal cancer

Shahin Hajibandeh¹ • Shahab Hajibandeh² • Mokhtar Eltair¹ • Anil T. George¹ • Vijay Thumbe¹ • Andrew W. Torrance¹ • Misra Budhoo¹ • Howard Joy¹ • Rajeev Peravali¹ 2020

Conclusion

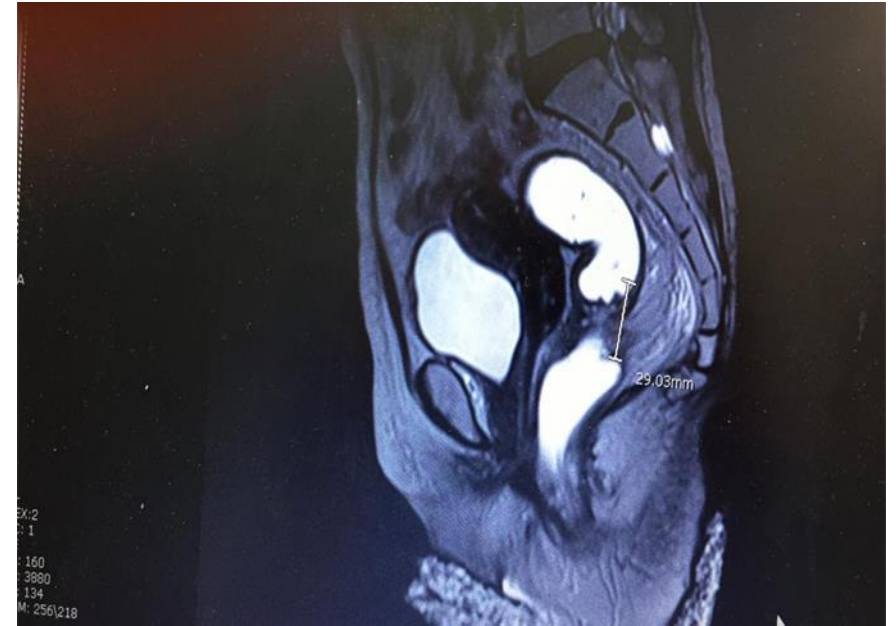Meta-analysis demonstrated that TATME may be associated with significantly higher rate of R0 resection, lower rate of positive CRM, higher rate of harvested lymph nodes in management of middle and low rectal cancer.

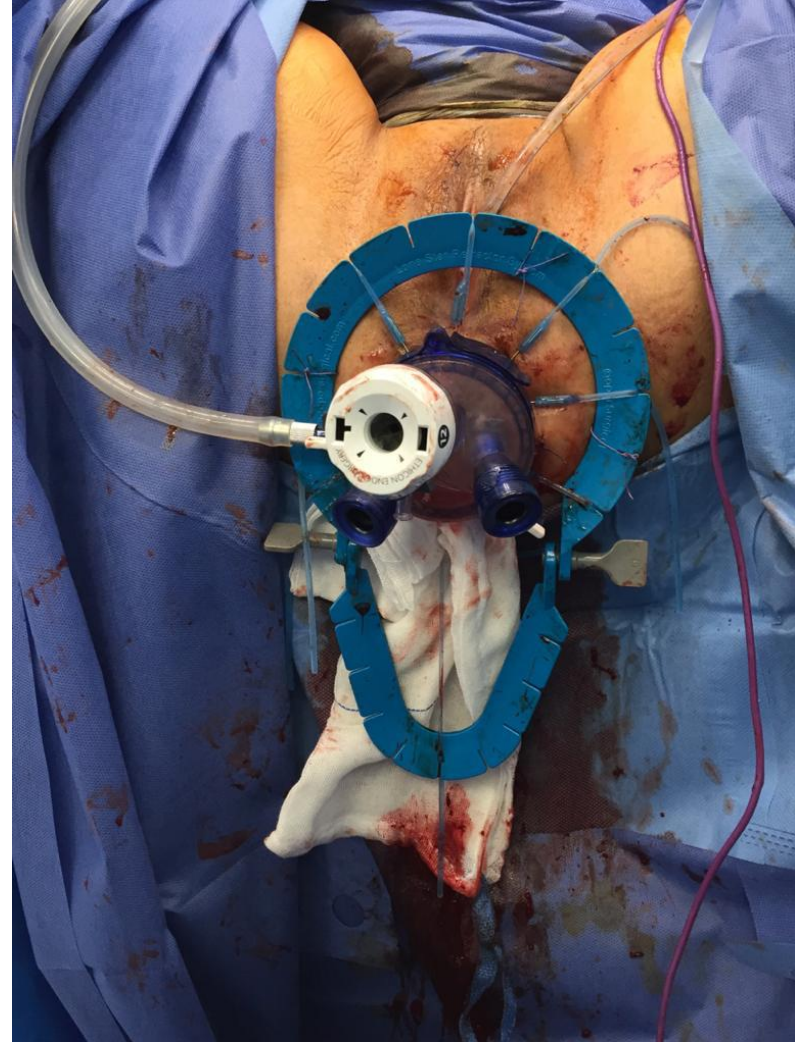
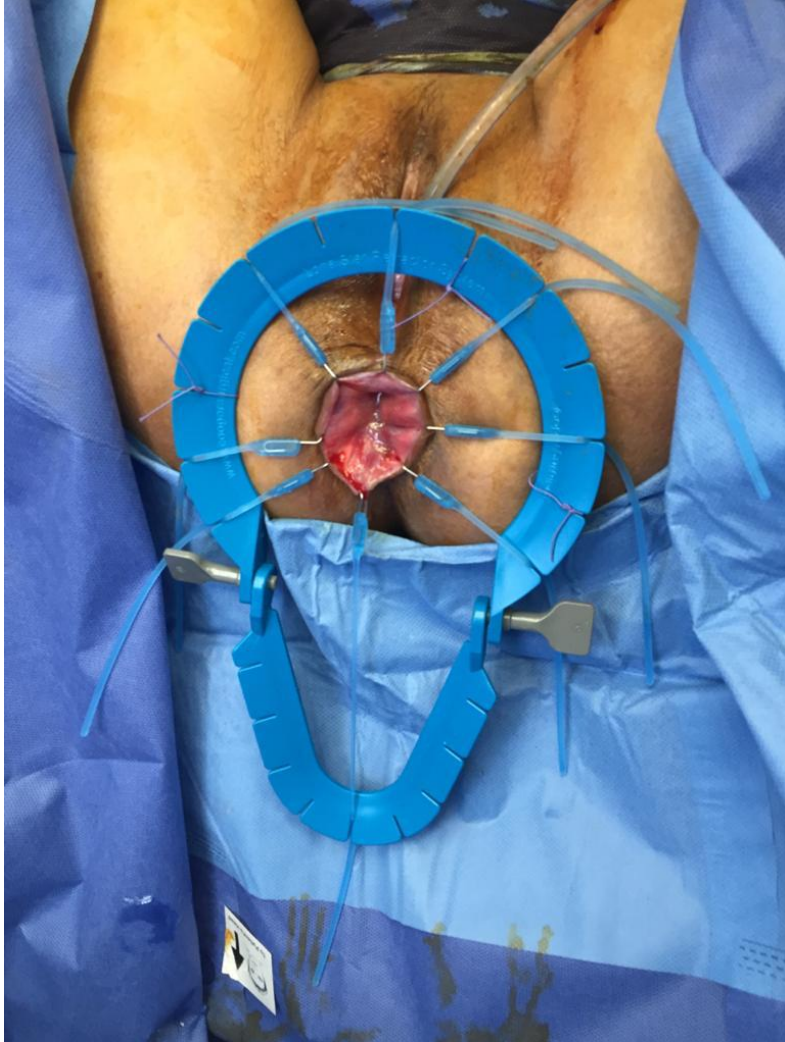

CASE

Brief history

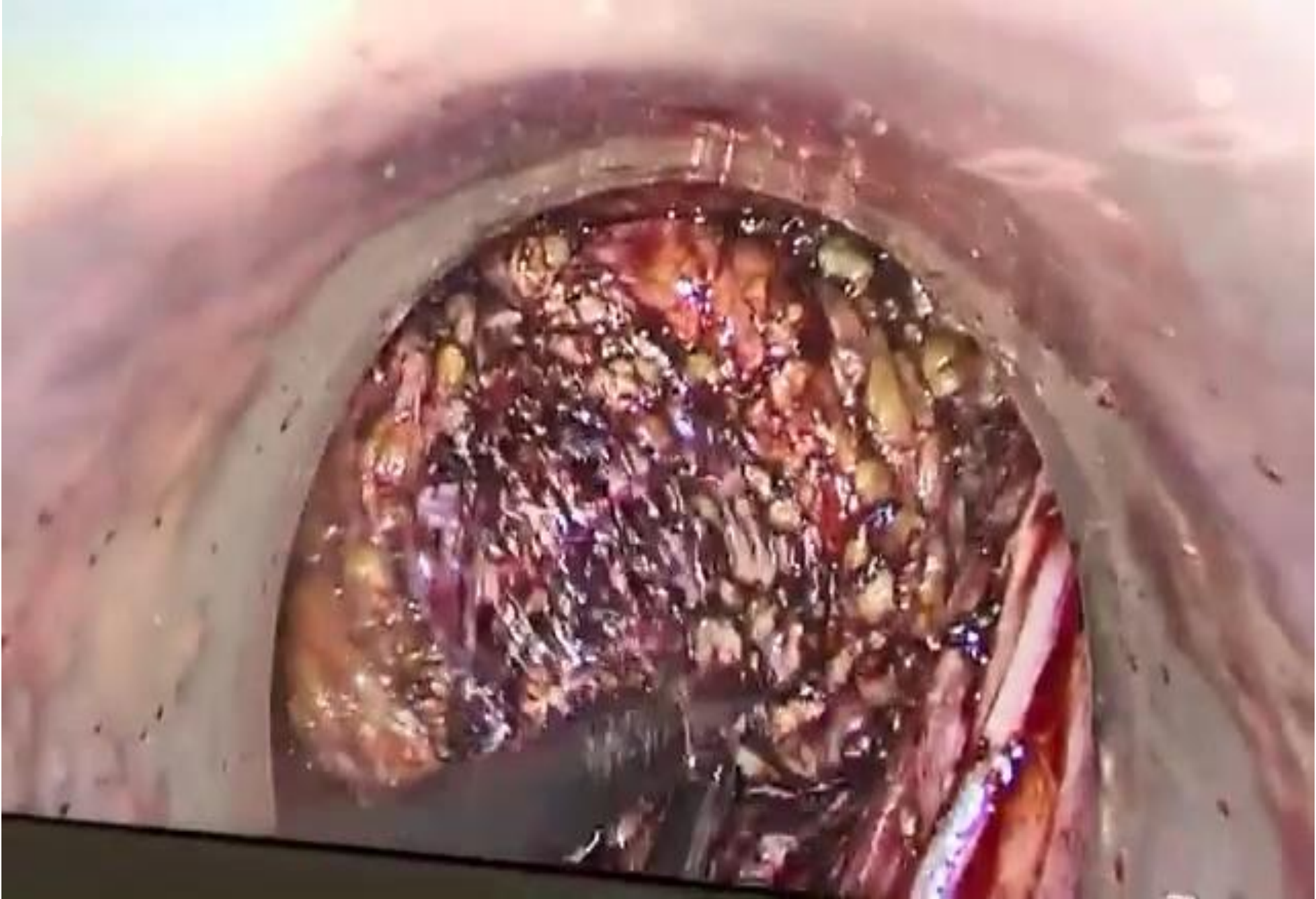- 50 y female, BMI : 17.6
- MRI before nCRT : Circumferential mural thickening involving anorectal region and lower rectum and Enlarged mesorectal LN
- Colonoscopy disclosed Lower rectal fungating ulcerative mass 3 cm from anal verge, rest of examination: free.
- Pathology: rectal adenocarcinoma GII
- Minimal regression in follow up MRI after nCRT
- Patient underwent combined laparoscopic & Transanal TME with preservation of the external sphincteric function.
- Pathology: Adenocarcinoma T2 N0, proximal and distal margin negative for malignancy.







**EMIRATES SOCIETY
OF COLON & RECTAL SURGERY**
جمعية الإمارات لجراحة القولون والمستقيم

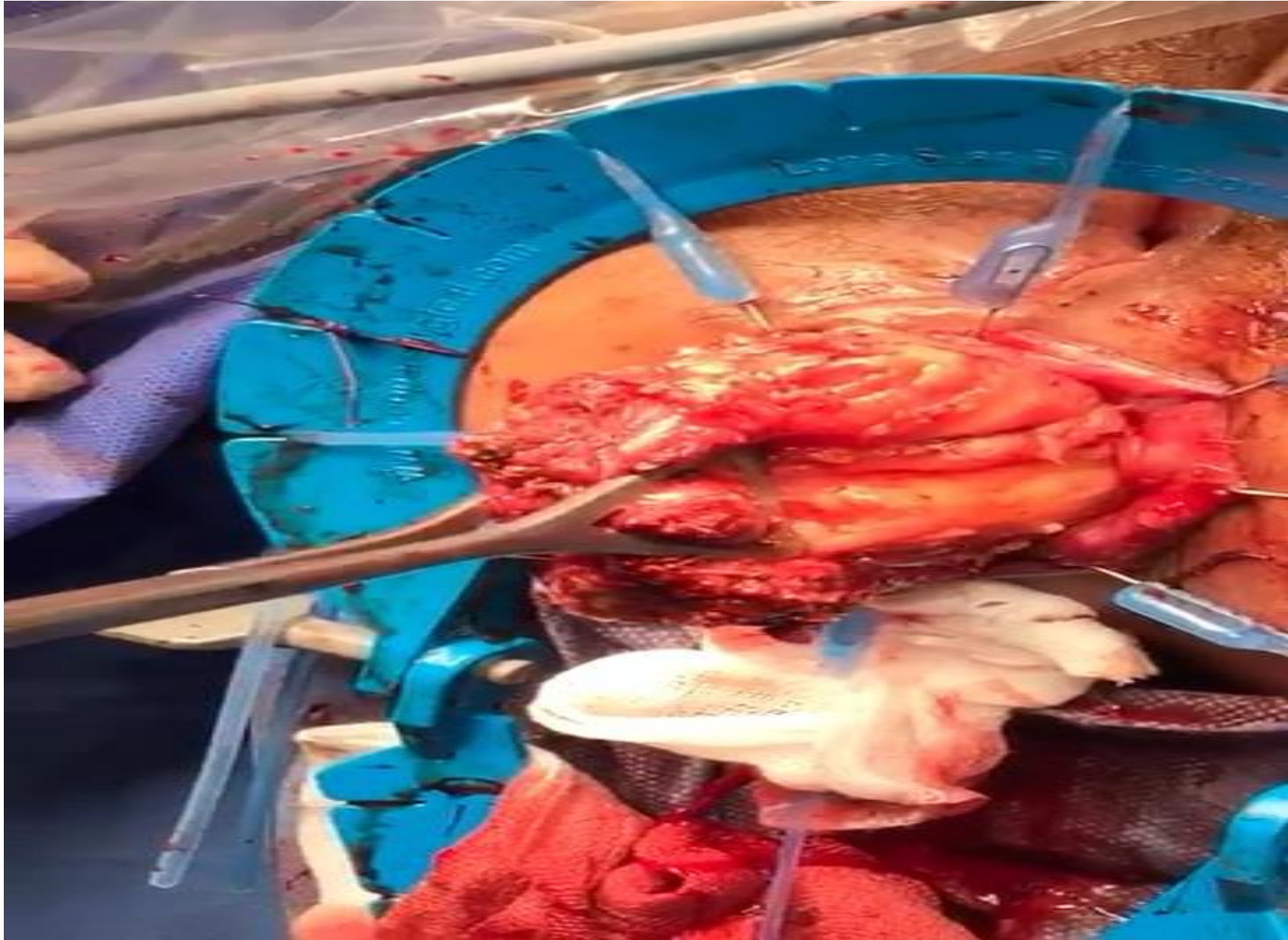


ميدىكلينيك
MEDICLINIC





EMIRATES SOCIETY
OF COLON & RECTAL SURGERY
جمعية الإمارات لجراحة القولون والمستقيم



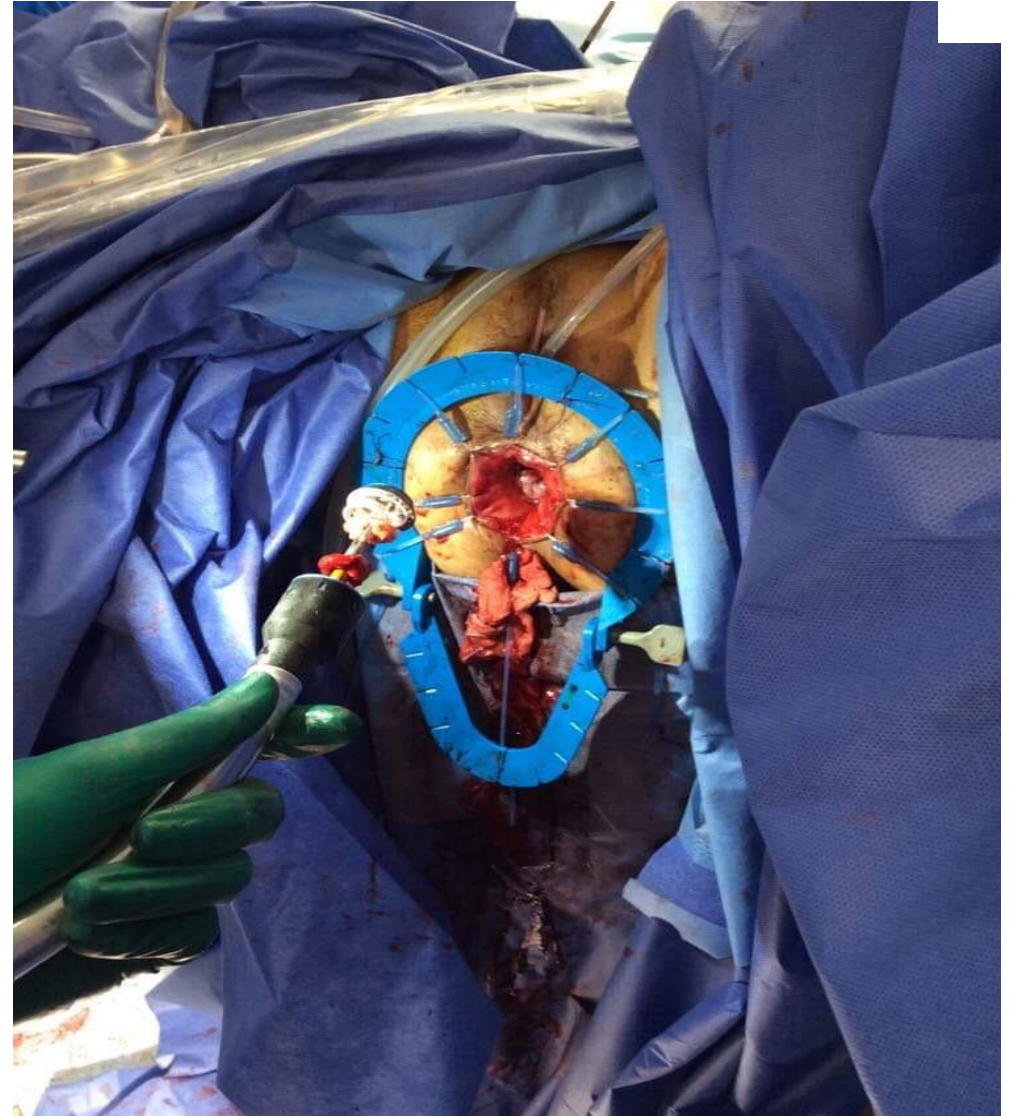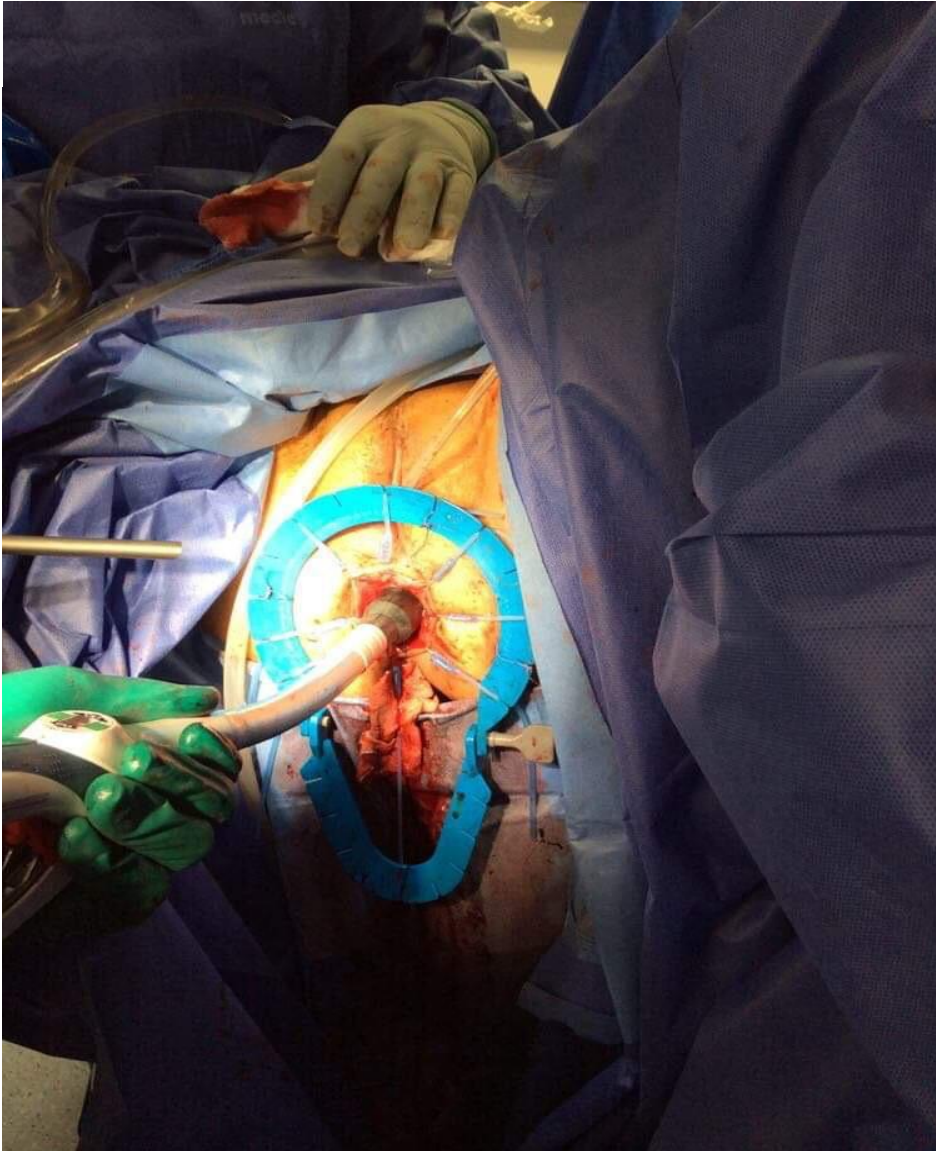
ميدىكلينىك
MEDICLINIC





**EMIRATES SOCIETY
OF COLON & RECTAL SURGERY**
جمعية الإمارات لجراحة القولون والمستقيم

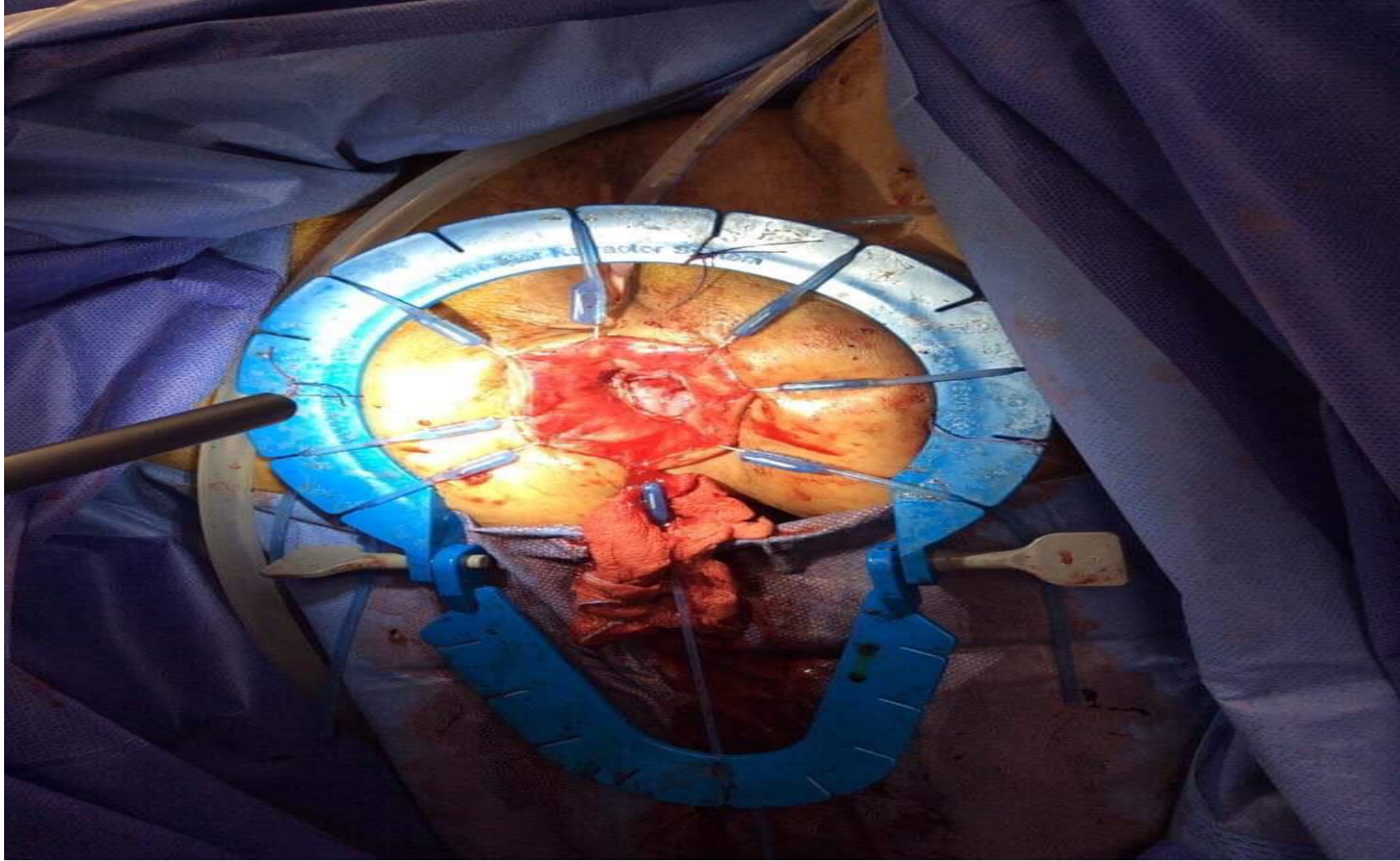
ميدىكلينيك
MEDICLINIC





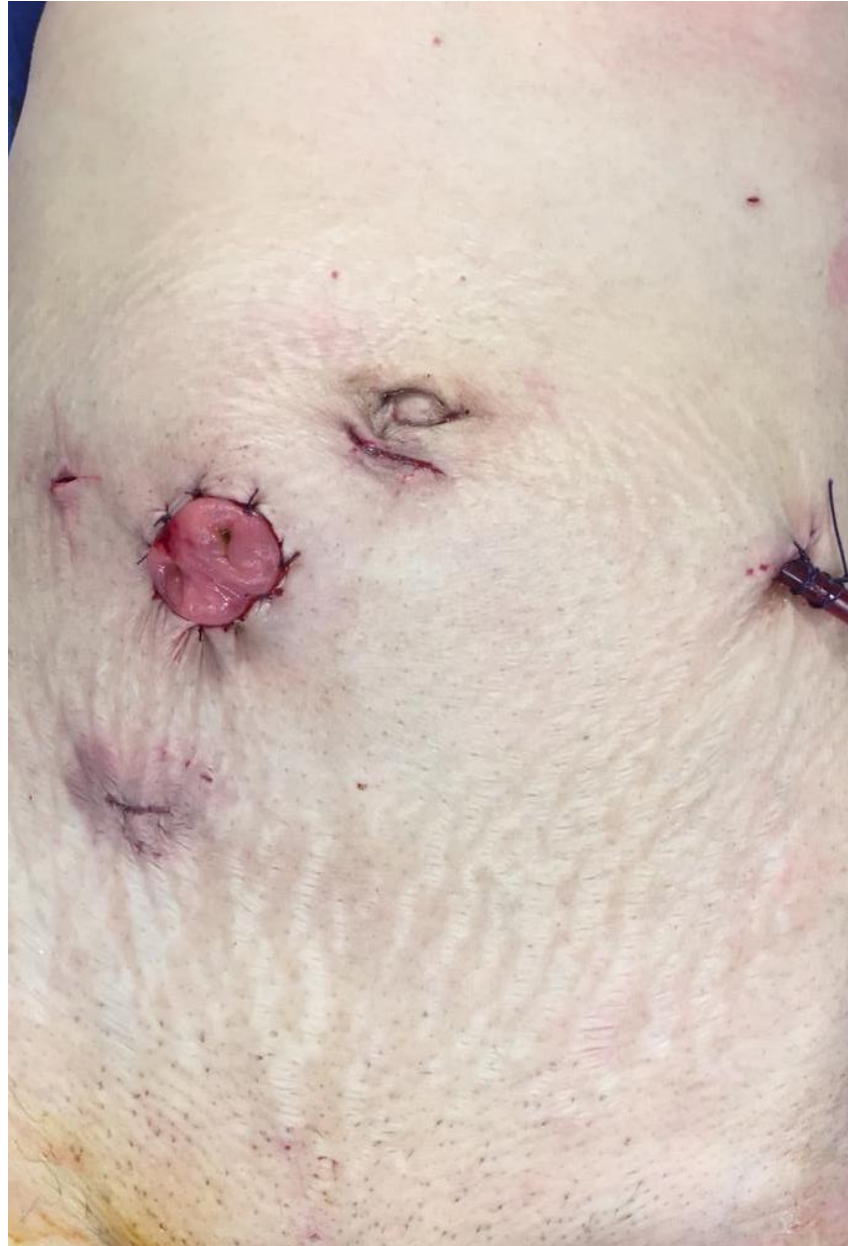EMIRATES SOCIETY
OF COLON & RECTAL SURGERY
جمعية الإمارات لجراحة القولون والمستقيم

ميدىكلينىك
MEDICLINIC





**EMIRATES SOCIETY
OF COLON & RECTAL SURGERY**
جمعية الإمارات لجراحة القولون والمستقيم





EMIRATES SOCIETY
OF COLON & RECTAL SURGERY
جمعية الإمارات لجراحة القولون والمستقيم

CONCLUSION

Achieving a high-quality TME resection specimen is a central belief of curative rectal cancer management.

However,

Operating at the caudal extremity of the pelvis is challenging and a number of patient- and tumor-related factors may increase the risk of obtaining a poor TME specimen and positive resection margin.



SAVE THE DATE

3rd Emirates International Colorectal Congress In Dubai



FEBRUARY 7-8, 2026





**EMIRATES SOCIETY
OF COLON & RECTAL SURGERY**
جمعية الإمارات لجراحة القولون والمستقيم

ميداكلينيك
MEDICLINIC

A wide-angle photograph of the Dubai skyline at dusk. The sky is a mix of soft purple, pink, and blue. Several skyscrapers are illuminated with warm yellow and orange lights. On the right, the Burj Khalifa is visible, along with other modern buildings. In the foreground, there are palm trees and a body of water reflecting the city lights.

Thank You