



جامعة القاهرة

INTEGRATED CLINICAL & RESEARCH
CENTER FOR INTESTINAL DISORDERS



Endoscopic Submucosal Dissection for Colorectal Neoplasia

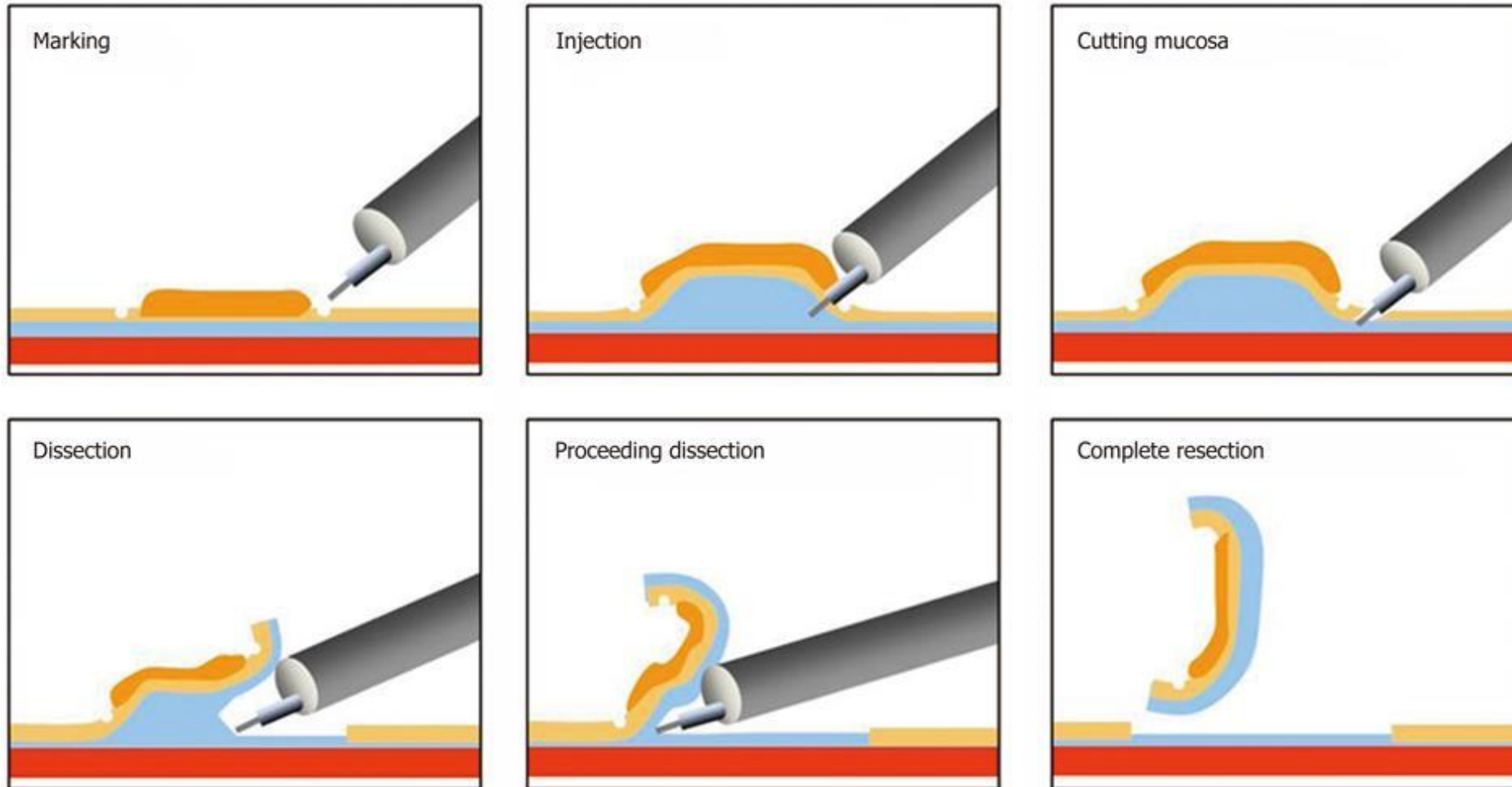
Dr. Hany Shehab MD, FRCP

Professor of Gastroenterology

Director of the Integrated & Clinical Center for Intestinal Disorders (ICRID)

Cairo University

ESD: Basic principle

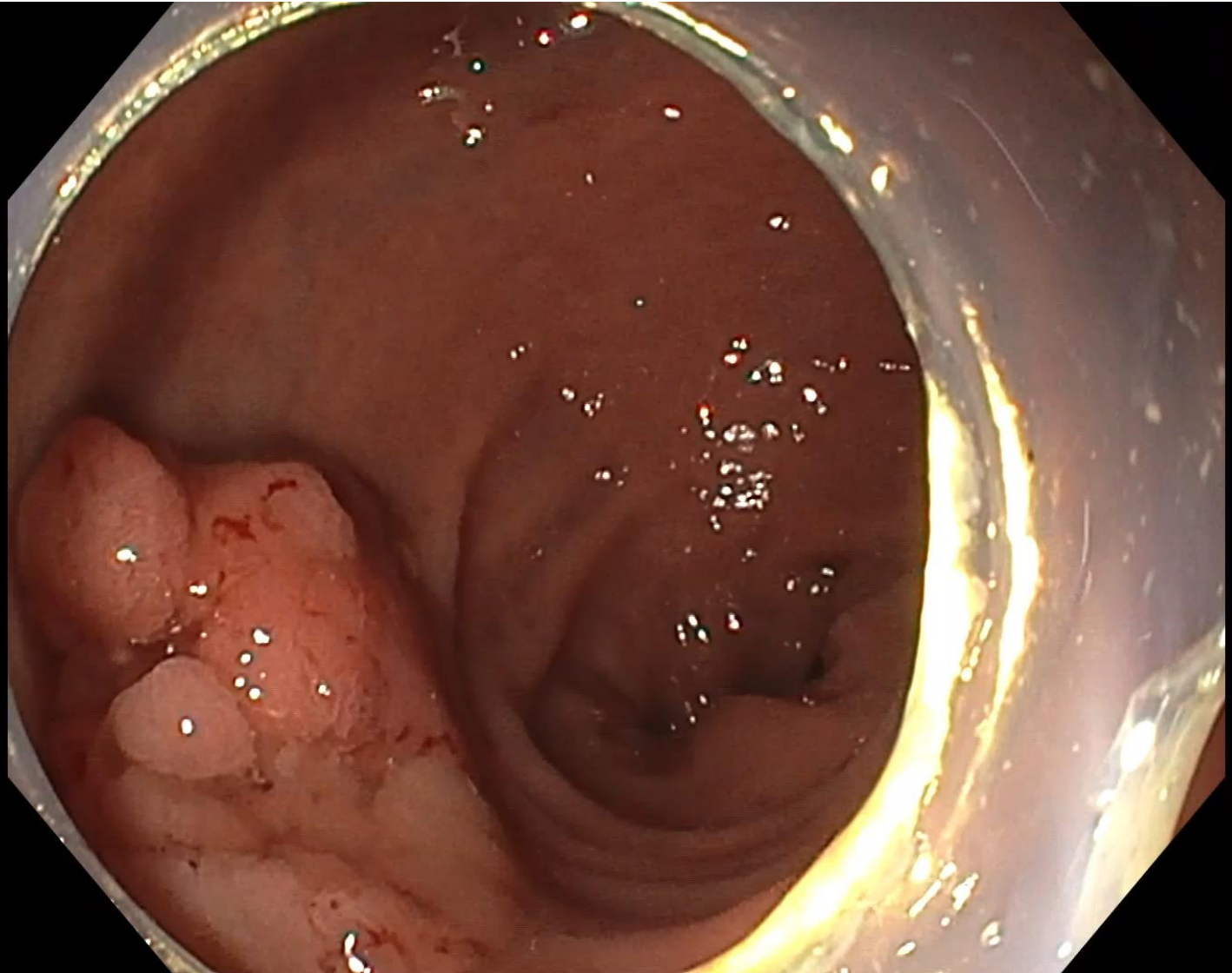


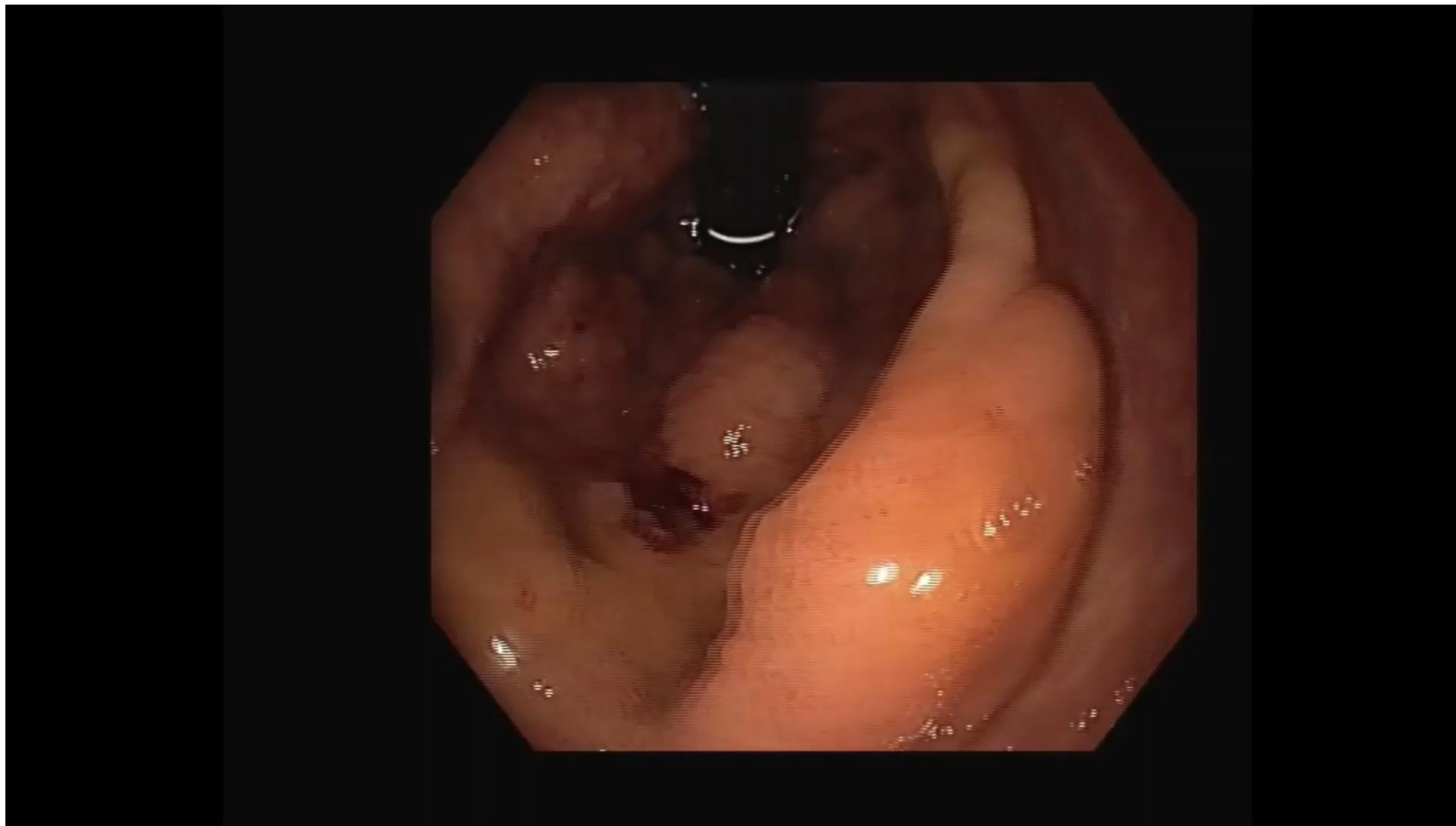
25/07/2023 11:48:32
Issuing temporary patient ID

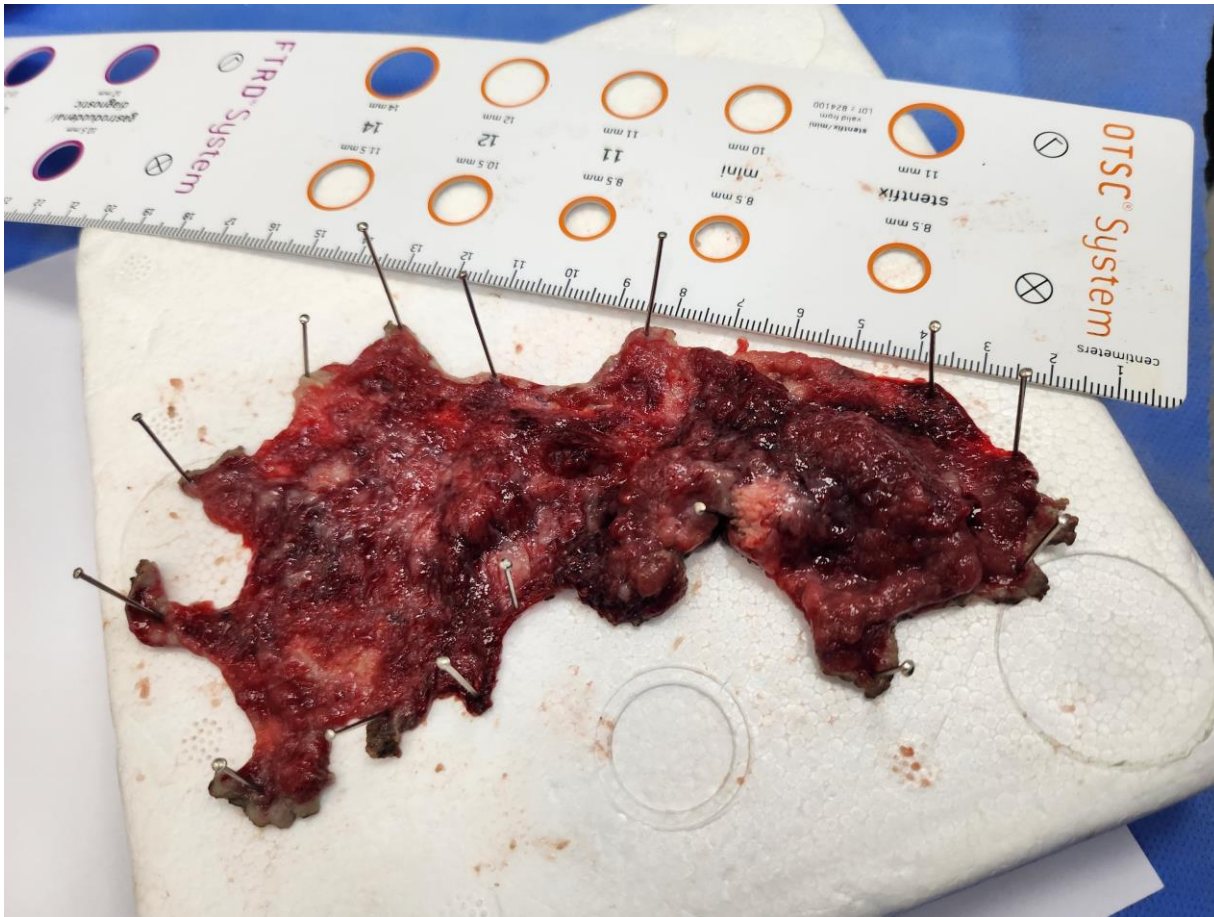
4
A3

A set of standard mobile device status icons: a camera icon, a battery level icon, and a cellular signal strength icon.

- GIF-1TH190
- 2244880
- 3.7
- 10.0/10.9
- 1 Freeze
- 2 NBI
- 3 RDI
- 4 Release 1







Nature of the specimen: Endoscopic submucosal dissection

PATHOLOGY REPORT

GROSS:

Pinned on a board a flat mucosal tissue piece showing a lesion with granular surface, inked deep margin, serially sectioned, and totally submitted.



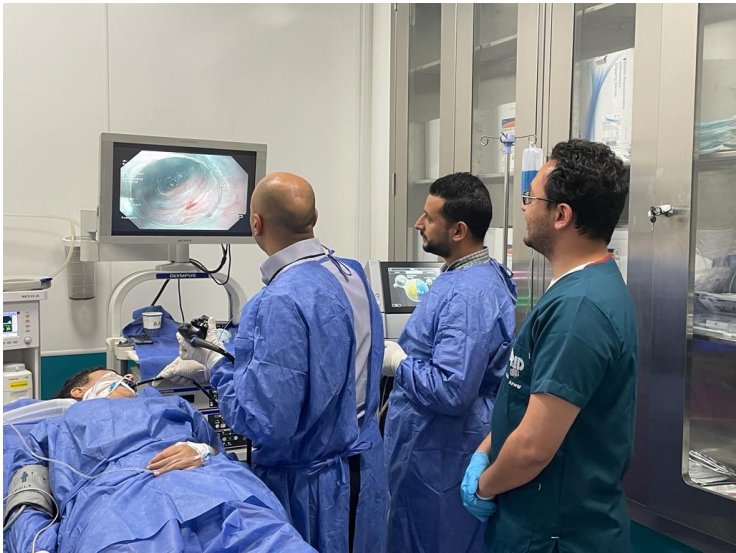MICROSCOPY:

Sections examined from the referred ESD reveal a polypoid growth formed of finger-like epithelial projections (villi comprising 25-50% of the dysplastic tissue) with focal serrations and dilated crypt bases, lined by columnar cells with dark elongated nuclei (low grade dysplasia), together with small foci of fused glands, enlarged nuclei, and nucleoli (high grade dysplasia). The surrounding stroma shows mononuclear inflammatory cells, lymphoid follicles, neutrophils, eosinophils, with no desmoplasia / invasion. Lateral margins show normal rectal mucosal glands. The inked deep margin is free (completely excised).

CONCLUSION: Rectal TVA with high grade dysplasia; ESD:

TUBULOVILLOUS ADENOMA, LOW GRADE DYSPLASIA, WITH FOCI OF HIGH-GRADE DYSPLASIA

FREE LATERAL AND DEEP MARGINS (COMPLETELY EXCISED)




Thank You !

Full-Thickness Resection for Colonic Non-lifting Lesion

Prof. Dr. Hany Shehab MD, FRCP

Cairo University



01/08/2023 09:59:12
Issuing temporary patient ID

11
A3

- GIF-1TH190
- SN 2244880
- 3.7
- 10.0/10.9
- 1 Freeze
- 2 NBI
- 3 RDI
- 4 Release 1

