

Surgical and functional outcome of laparoscopic vaginal suspension combined with suture rectopexy for management of pelvic organ prolapse.

Mohamed I Abuelnasr, Ahmed M Nawar, Ahmed F. Salama

Presented by



Dr. Mohamed I. Abuelnasr

Lecturer of colorectal surgery, Benha University






Introduction





Pelvic Organ Prolapse (POP) is one of the most common pelvic dysfunctions that adversely affect women's quality of life by limiting their physical and psychosocial activities and sexual function.

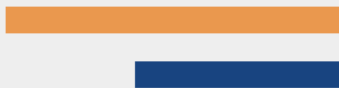POP may involve the anterior vaginal wall, posterior vaginal wall, and vaginal apex (apical prolapses); the posterior vaginal wall prolapse refers to rectal protrusion into the vagina (rectocele).



The purpose of surgery for pelvic organ prolapse is to correct the prolapse and to recover defecation dysfunction postoperatively with Simultaneous correction of middle-pelvic-compartment prolapse.









Pelvic organ prolapse suspension (POPS) surgery, described by Longo, is a surgical procedure for multi compartmental female pelvic prolapse. The technique is much easier than traditional treatments with significant improvement of the preoperative symptomatology. After POPS surgery, if a residual rectoanal prolapse and/or an anterior rectocele persist, then a stapled transanal rectal resection (STARR) is performed.



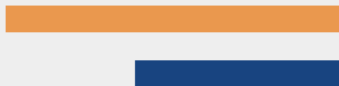

STARR procedure involves a double stapling technique with the use of two circular stapler to remove the anorectal mucosa circumferential and reinforce the anterior anorectal junction wall correcting the structural abnormalities associated with ODS, on the other hand using two circular staplers which cost in Egypt about **1250 US** dollars, that is considered a very expensive cost in such low income country and not covered by insurance company in most cases.



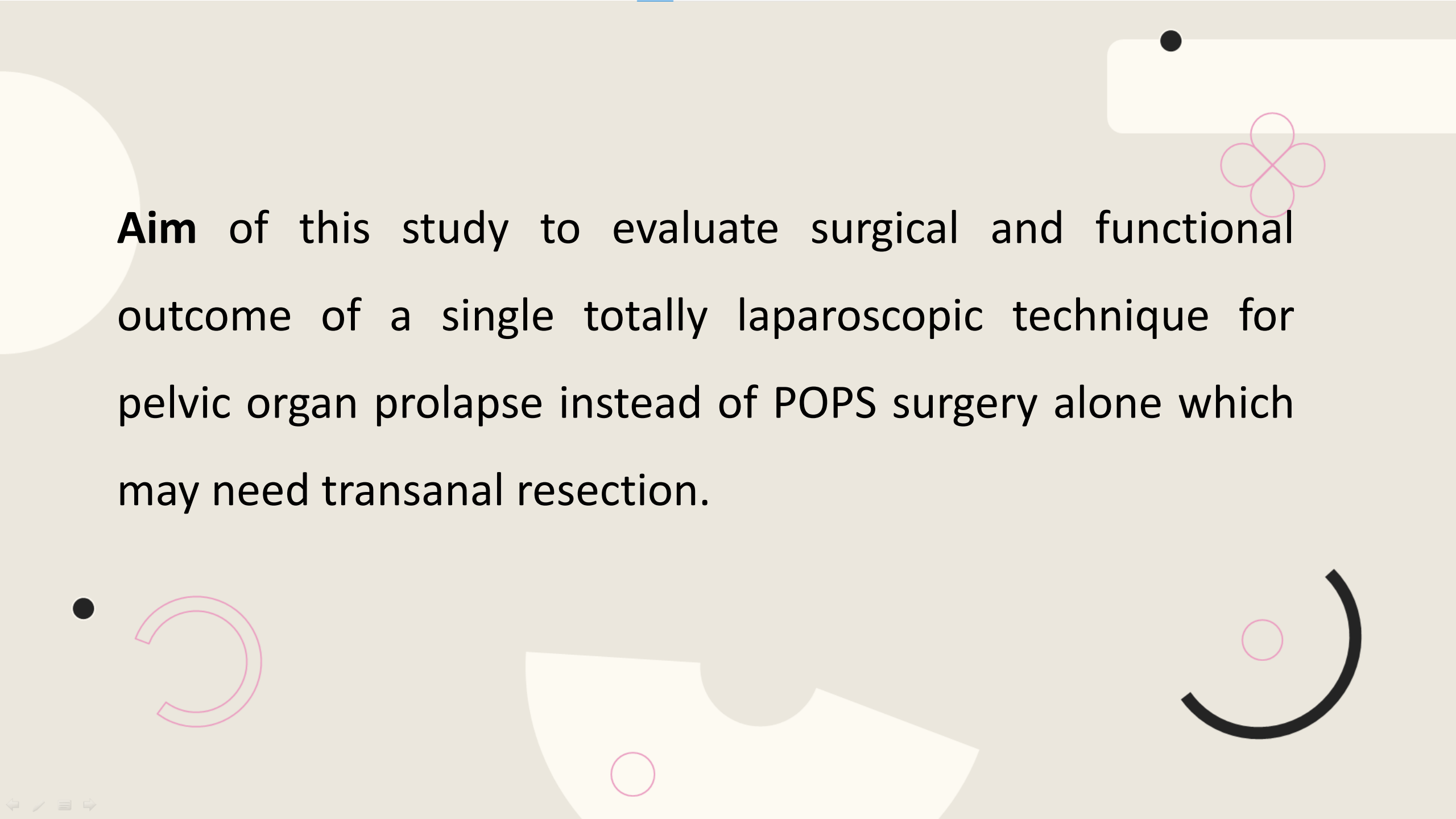


Based on this background, for patients with multi organ prolapse in which residual rectal prolapse still present after vaginal suspension, dispensing with STARR procedure we modify the POPS procedure and proposed a new combined totally laparoscopic technique, laparoscopic vaginal suspension with rectopexy in which middle and posterior pelvic compartments prolapse can be corrected.







AIM of the study







Aim of this study to evaluate surgical and functional outcome of a single totally laparoscopic technique for pelvic organ prolapse instead of POPS surgery alone which may need transanal resection.



Patients and methods

- 
- 
- The current prospective clinical cohort study was conducted at colorectal surgery unit, Surgery Department, Benha University Hospital, after obtaining approval from the local ethical committee and after fully informed written consent was signed by the patient throughout the period from March 2018 till March 2022 including follow up period.



- 
- 
- This prospective study was conducted upon 35 female patients with multiorgan pelvic prolapse with obstructed defecation symptoms in which residual rectal prolapse still present despite reduction of uterine prolapse during examination under general anesthesia.
 - Patients with recurrent rectal prolapse, Patients who were unfit for surgery, patients with history of pelvic radiotherapy and patients complaining from fecal incontinence were excluded from the study.
- 
- 

Study outcome

Surgical outcome:

- Intraoperative (IO) collected data included operative time, IO blood loss, and frequency of IO complications
- Postoperative (PO) data included, pain score, PO hospital stay, the frequency of PO complication and time needed for mesh incorporation
- Postoperative (PO) follow-up extending for 12 months for the incidence of recurrence of ODS and recurrence of prolapse.

Functional outcome:

It was assessed at 6 months and 12 months postoperative and compared versus preoperative, we evaluate:

- Obstructed defecation symptoms by modified longo score.
- Anorectal manometry
- Need of using laxative postoperative
- Sexual function by Female Sexual Function Index (FSFI) which is a 19-item self-report inventory designed to assess female sexual function.*

*Sand, M., Rosen, R., Meston, C., & Brotto, L. A. (2009). The female sexual function index (FSFI): a potential “gold standard” measure for assessing therapeutically-induced

Methods

Preoperative assessment

1. Full history and assessment of obstructed defecation by modified longo score (6) in which a lifestyle change parameter to seven symptoms based parameters.

2. Clinical assessment

- By inspection, the patient is asked to bear down, the full thickness rectal wall prolapse and its concentric folds can be seen.
- Per rectum examination, to assess the integrity of anal sphincter, excluding presence of masses in anal canal and lower rectum and feeling the internal rectal prolapse while the patients bear down.
- Per vaginal examination during rest and during straining, anterior and posterior vaginal walls were observed for cystocele or rectocele.

Methods

3. Anorectal manometry was done preoperative and postoperative at 6 month and 12 month using **Solar GI HRAM MMS** with 24- channel water perfused catheter with latex balloon to evaluate rectal sensations, anal sphincter pressures and for exclusion of anismus.

4. Imaging

All patients were subjected to MR defecography.

Methods

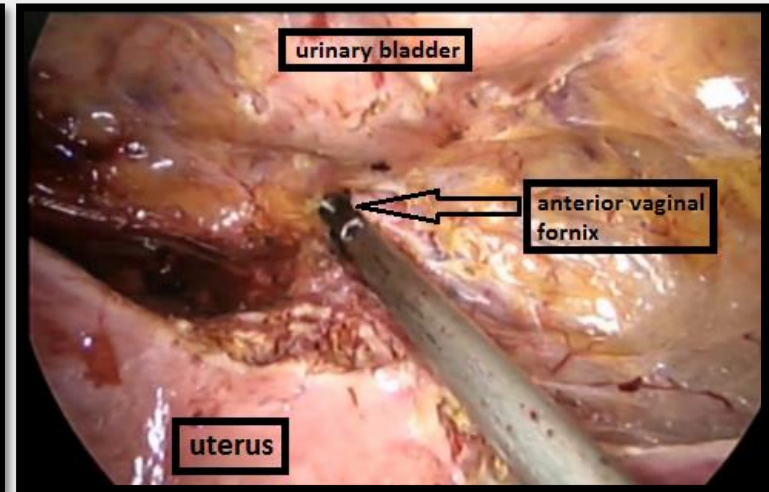
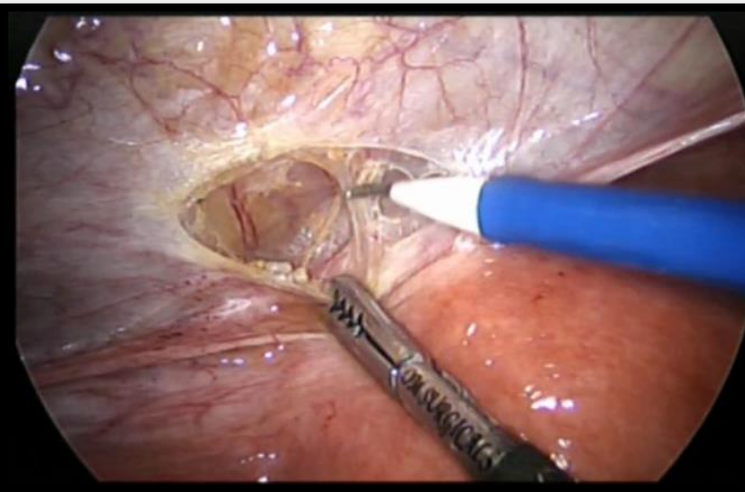
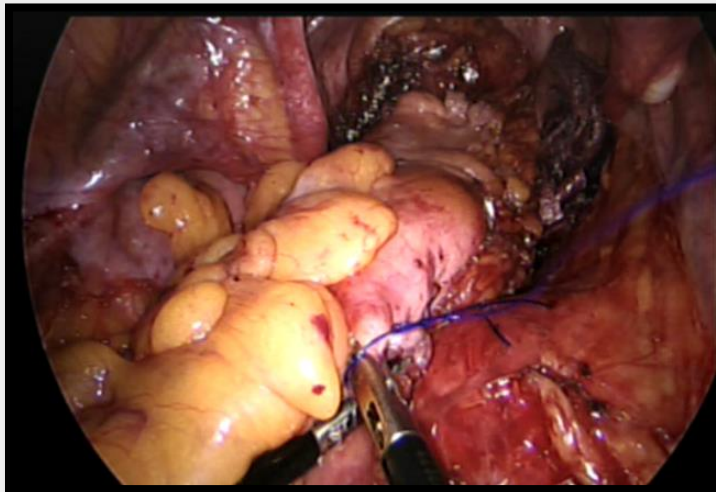
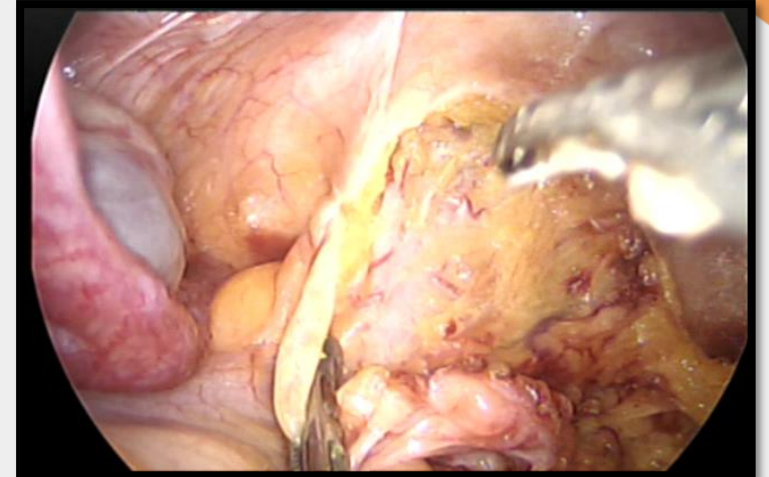
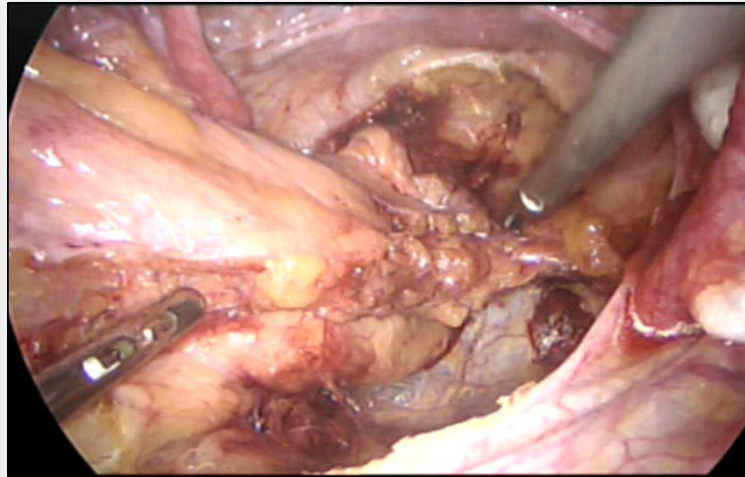
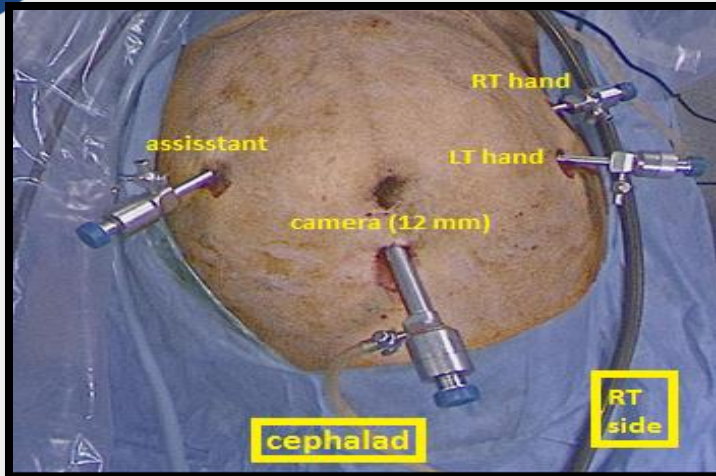
5. Colonoscopy

Done for all patients to exclude any proximal lesions and for biopsy from the rectal ulcer to exclude malignancy.

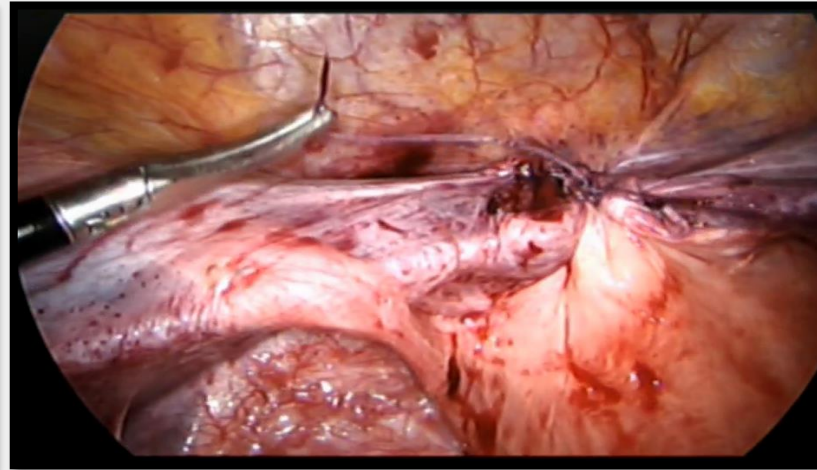
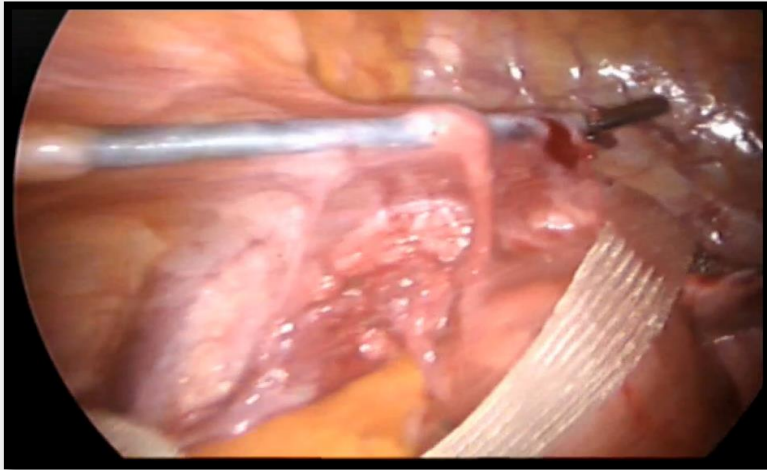
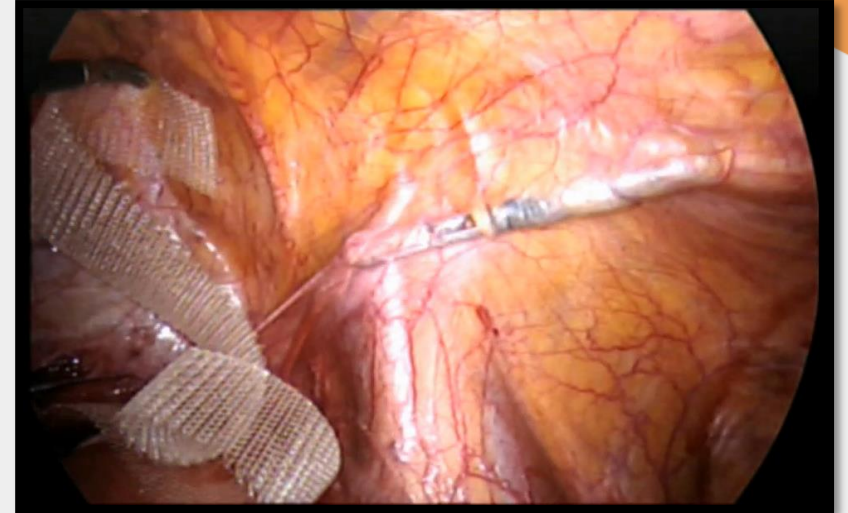
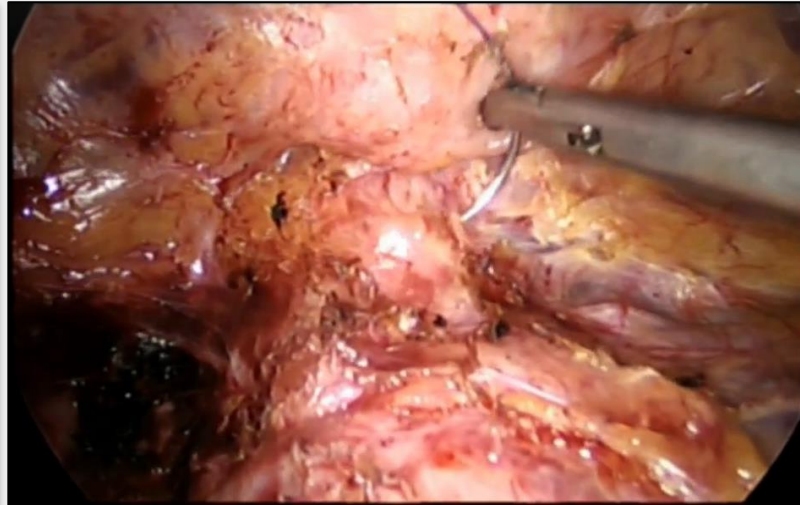
6. Assessment of Sexual function by FSFI, done preoperative and postoperative at 6-month and 12-month postoperative.

7. Routine preoperative laboratory tests.

Laparoscopic surgical technique



Laparoscopic surgical technique





Follow up

- Patients reassessed by anorectal manometry and modified longo score for ODS. Also Sexual function evaluated by Female Sexual Function Index (FSFI). The questionnaire was handed out to patients by a nurse and self-administered in the outpatient clinic.
- Recurrence was assessed clinically and followed up to 1 year or till the end of the study.
-





Results

Table 1: Baseline characteristics in the study participants

Data are presented as mean ± SD or n (%), BMI: Body mass index, OBD: Obstructive bowel disorder

	n =35
Age (years)	33 ± 8.12
Gender (Female)	35 (100%)
BMI (kg/m²)	39.03 ± 11.81
Comorbidities	9 (25.7%)
Main complaint	
OBD	26 (74.3%)
OBD + Sexual complaint	9 (25.7%)

Table 2: Intra and post operative data in the study participants

Data are presented as mean \pm SD, median (IQR), or n (%), ASA: American Society of Anesthesiologists

	n =35
*Operative data	
ASA score	12 (34.3%)
1	19 (54.3%)
2	4 (11.4%)
3	90 (90 - 100)
Operative time (minutes)	20 (20 - 30)
Blood loss (mL)	0 (0%)
Conversion to open	
*Intraoperative complications	
Bleeding	2 (5.71%)
Intestinal injury	0 (0%)
Uterine or bladder injury	0 (0%)
*Post operative data	
Post operative pain score	4 (2 - 4)
Trocar site infection	2 (5.7%)
Hematoma	1 (2.9%)
Hospital stay (days)	2.2 (2 - 3)
Recurrence	0 (0%)

Anorectal manometry preoperatively and in 6 and 12 months postoperatively

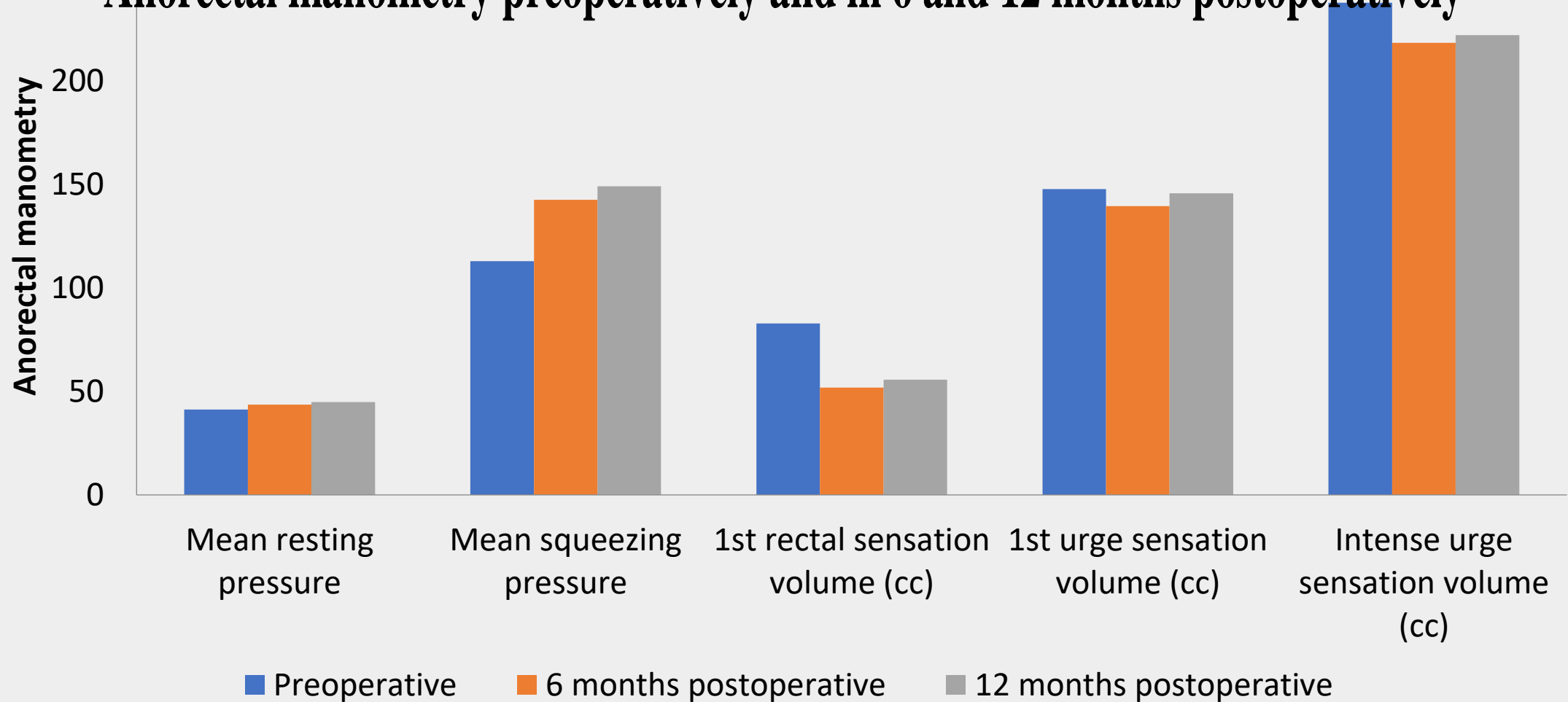
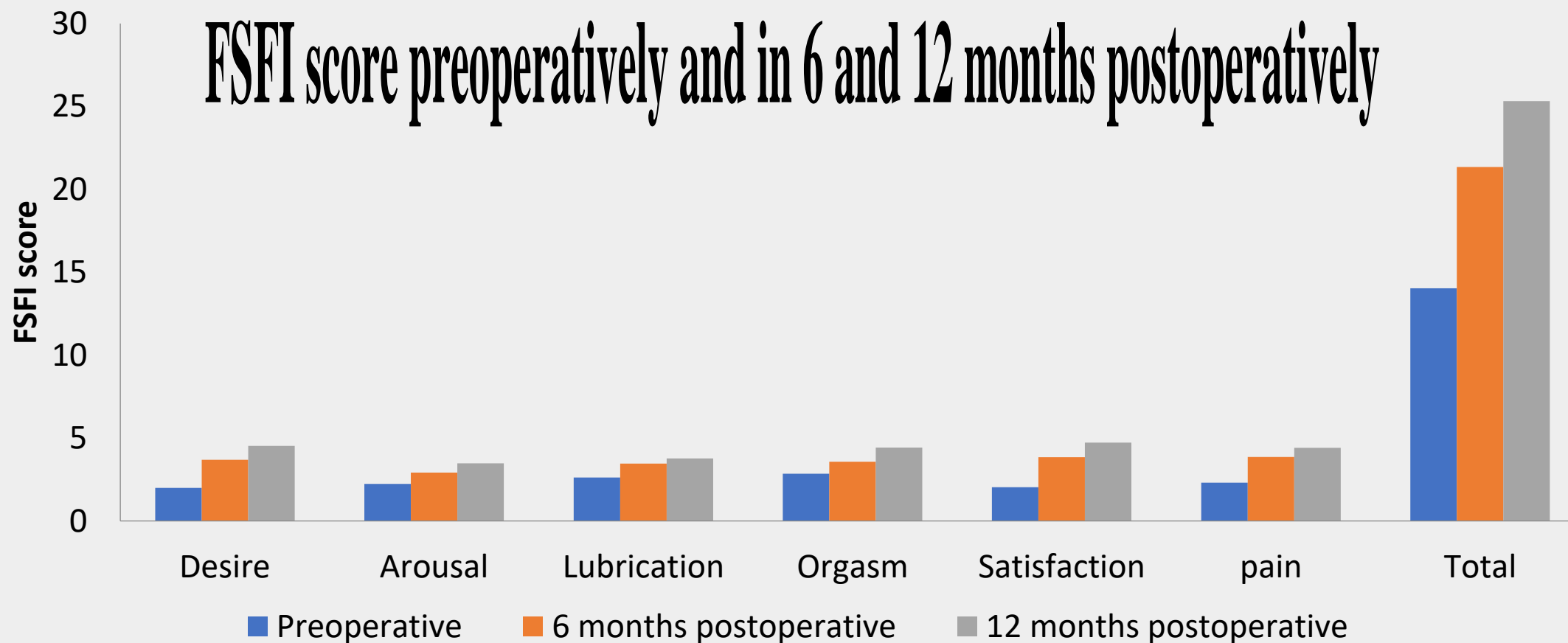


Table 4: Modified Longo score and need for laxatives preoperatively and in 6 and 12 months postoperatively

	Preoperative	6 months postoperative	12 months postoperative	P value
Modified longo score	18 (16 – 20) ^a	10 (8 – 12) ^b	8 (8 – 10) ^b	<0.001
Need for laxatives	35 (100%) ^a	6 (17.14%) ^b	5 (14.28%) ^b	<0.001

FSFI score preoperatively and in 6 and 12 months postoperatively





Conclusion

Conclusion

- ❑laparoscopic vaginal suspension combined with suture rectopexy is a totally laparoscopic procedure with excellent functional outcomes, minimal morbidity and a not very expensive cost when compared with POPS described by Longo (when STARR operation is needed).
- ❑It allows a short hospital stay and alleviates symptoms of obstructed defecation. The low recurrence rate, minimize both mesh-related complications and postoperative functional impairment and correction middle-compartment prolapses are advantages of the technique.



THANK YOU