

بِسْمِ اللَّهِ الرَّحْمَنِ الرَّحِيمِ

Laparoscopic total proctocolectomy and ileal-pouch anal anastomosis

By

Prof. Ayman El Nakeeb

**Gastroenterology Surgical Center,
Mansoura University**

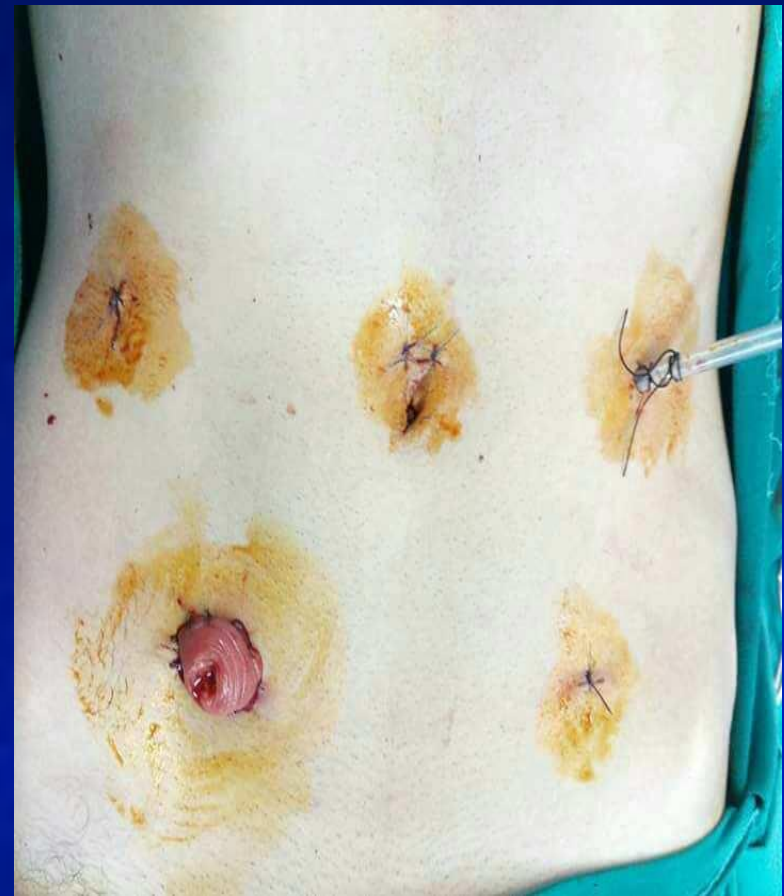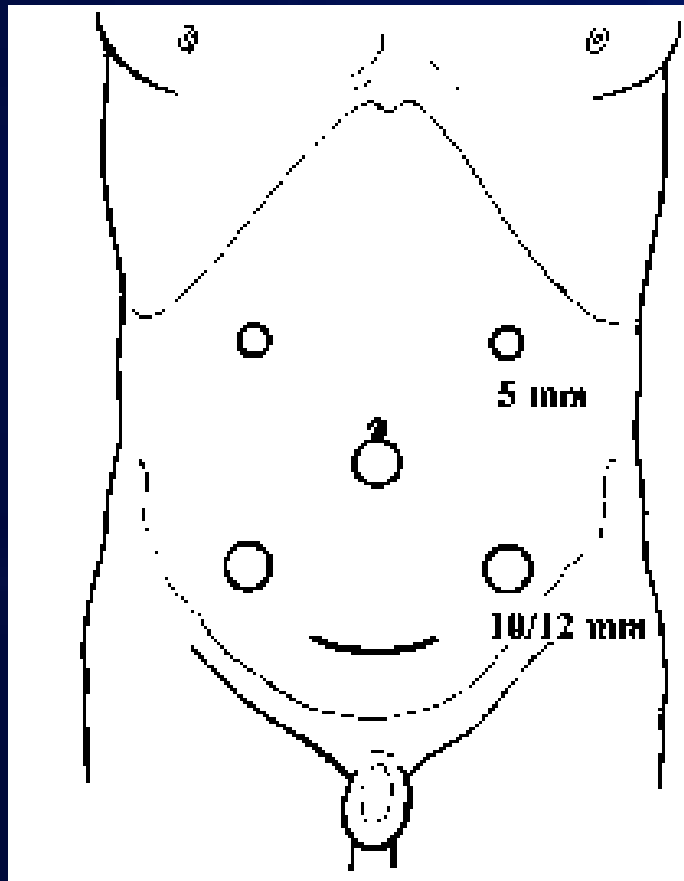
- Total proctocolectomy-IPAA is considered as a gold standard in the surgical management of ulcerative colitis and APC
- Total proctocolectomy-IPAA is a major surgery, associated with a significant re-operative rate for various consequences such as adhesions, sub-acute intestinal obstruction, and wound dehiscence.

- In recent years laparoscopic proctocolectomy-IPAA has been used as an alternative to conventional open techniques.

- **Twenty one patients underwent laparoscopic total proctocolectomy-IPAA in GEC, Mansoura University, Egypt, January 2010 and February 2017**
- **17 patients were UC and 4 patients were APC**

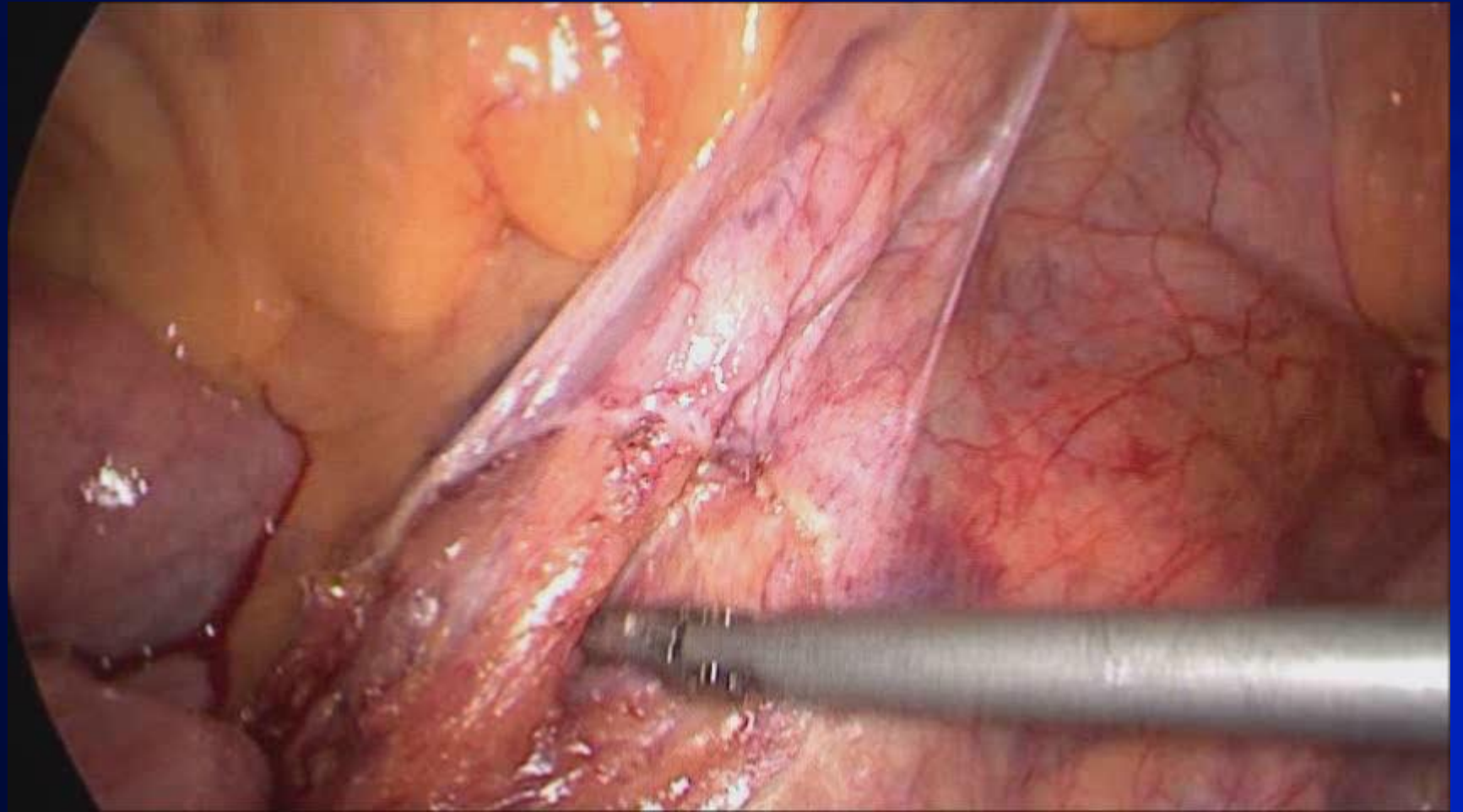
- **Female patients aged 32 years**
- **C/O: severe diarrhea (16 times) with bleeding per rectum**
- **Failed medical treatment**
- **Colonoscopy: severe hyperemia with multiple ulceration and multiple pseudopolyps**
- **Preoperative pathology: UC with mild focal dysplasia**

Port site design



- **First phase consisted of mobilization of the sigmoid colon and descending colon. The inferior mesenteric pedicle was divided into the process.**
- **The second phase consisted of mobilization of the splenic flexure and left half of the transverse colon.**

- **The third phase consisted of mobilization of terminal ileum, cecum, ascending colon, hepatic flexure, and the right half of transverse. The pedicles divided were the ileocolic, right colic, and middle colic vessels.**
- **The fourth phase consisted of mobilization of the rectum and transection of the rectum deep in the pelvis.**
- **The fifth phase consisted of specimen extraction, ileal J-pouch construction and pouch anal anastomosis and construction of ileostomy.**



- **The operative time was 4.5 hours**
- **Blood loss was 200 ml**
- **The day to resume oral intake was POD 2**
- **The hospital stay was 3 days**
- **Postoperative pathology was severe ulcerative colitis with high grade dysplasia with 7 reactive lymph node**

- Laparoscopic TPC-IPAA is feasible and safe in patients with ulcerative colitis and APC.
- There are still controversies regarding its impact on the length of hospital stay, overall morbidity and mortality.
- However, literature supports its positive impact on patient satisfaction, cosmesis, overall satisfaction. good functional outcomes, and excellent overall survival rates-in patients with APC.

Thank You