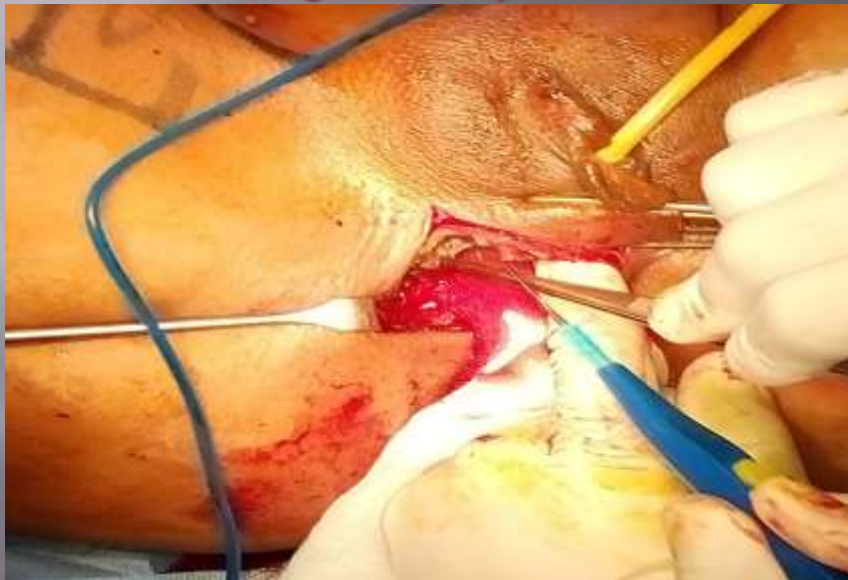

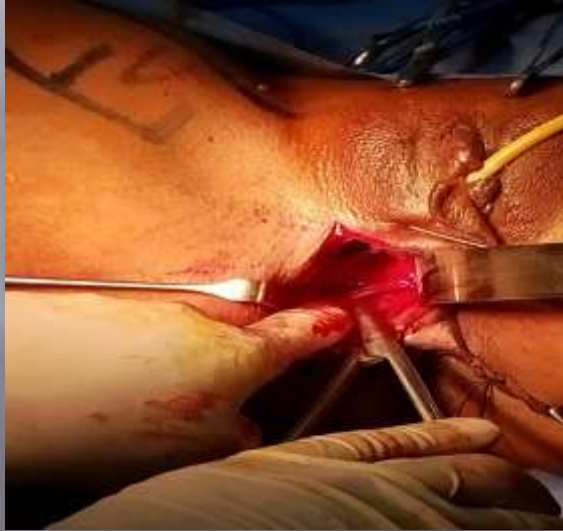GRACILOPLASTY IN MANAGEMENT OF RECURRENT RECTO-VAGINAL FISTULA

By
Ehab yousif
Assistant Lecturer, Colo-Rectal Surgical
Unit, Department Of General Surgery,
Banha University

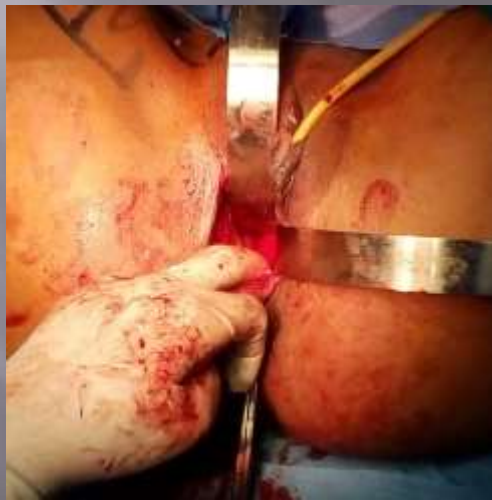Incision and dissection of recto- vaginal septum



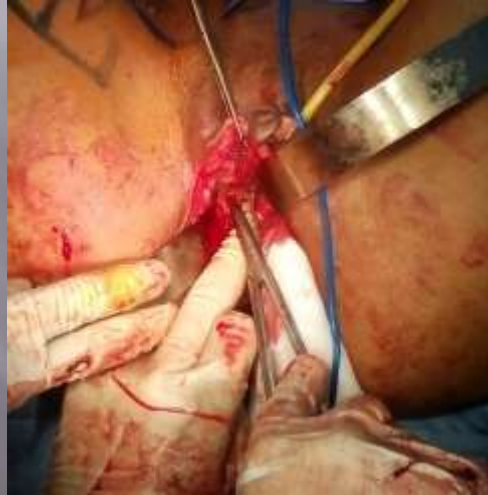Incision and dissection of recto-vaginal septum



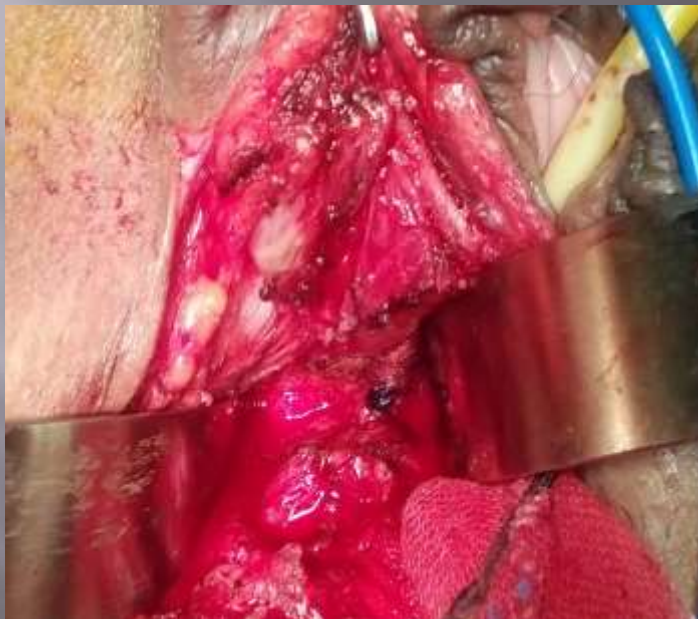Incision and dissection of recto-vaginal septum



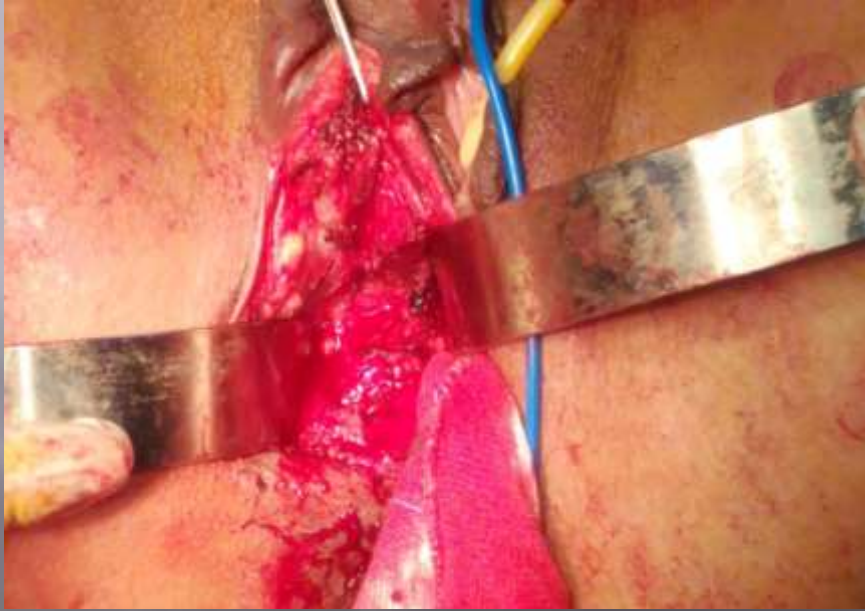
Incision and dissection of recto-vaginal septum



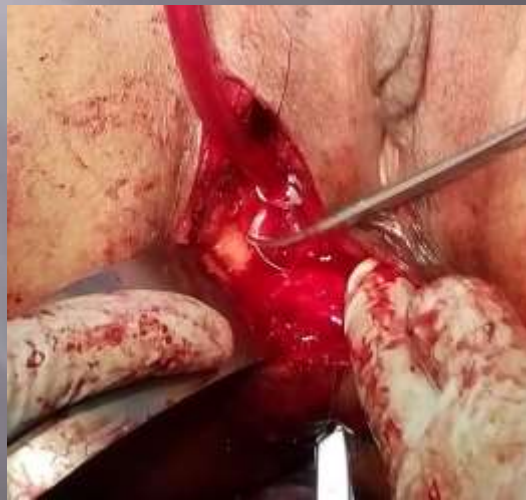Identification of the fistula tract



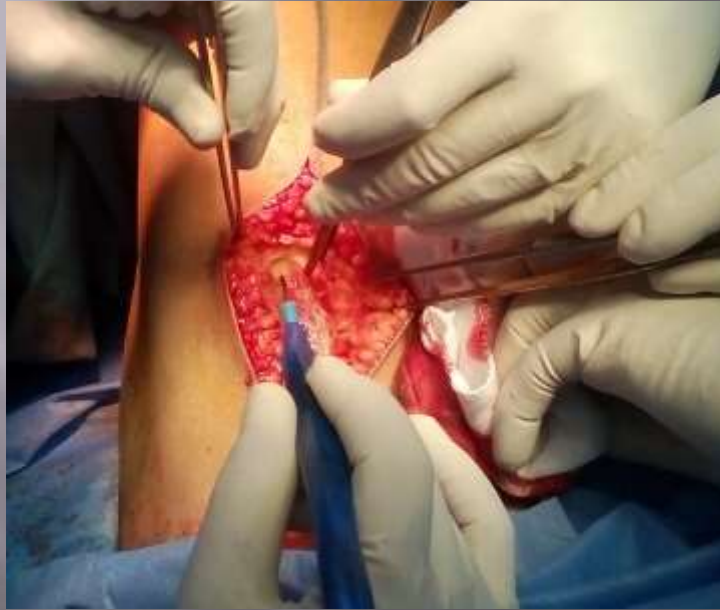Identification of the fistula tract



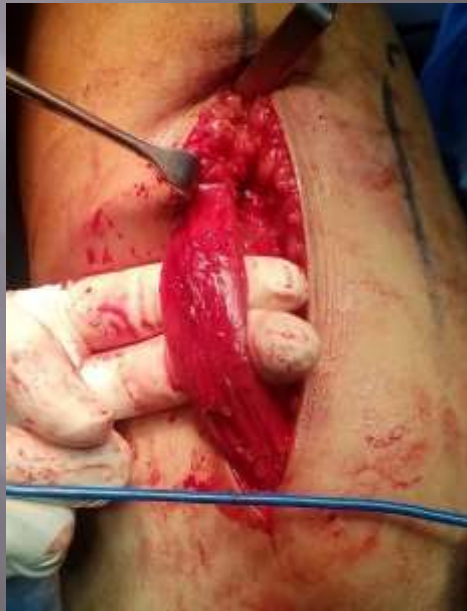Excision of the fistula and repair of rectal and vaginal defect



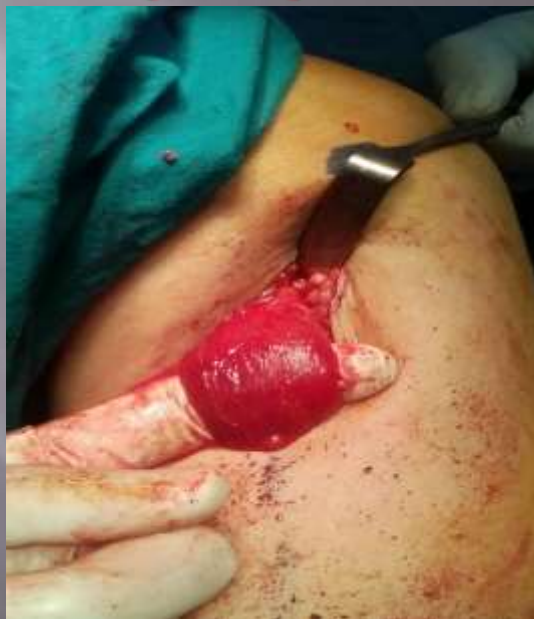Harvesting the gracilis muscle



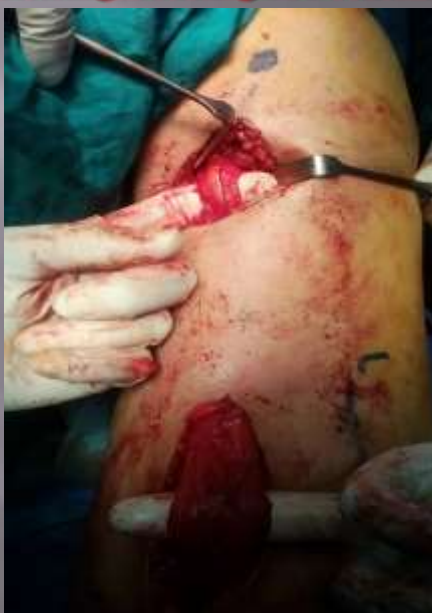Harvesting the gracilis muscle



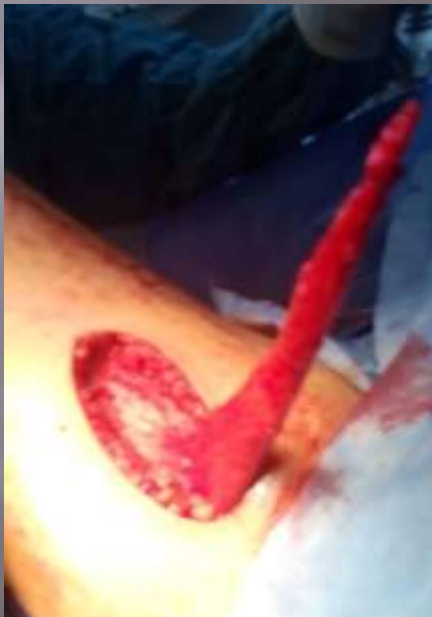Harvesting the gracilis muscle



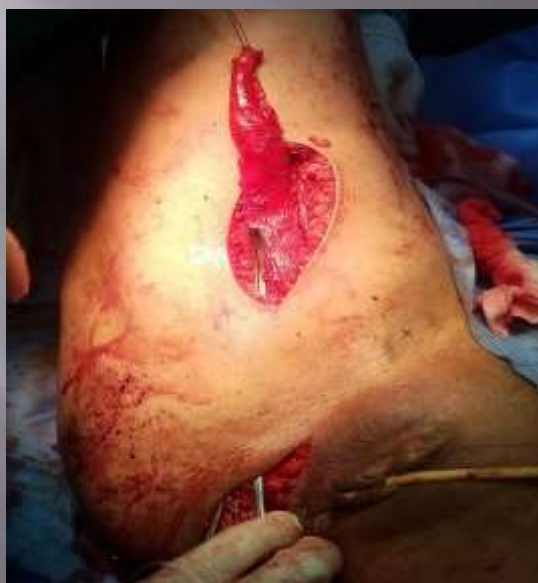Harvesting the gracilis muscle



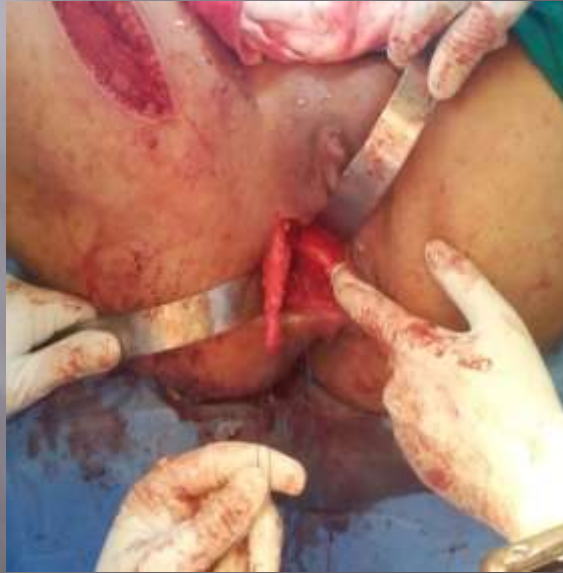Harvesting the gracilis muscle



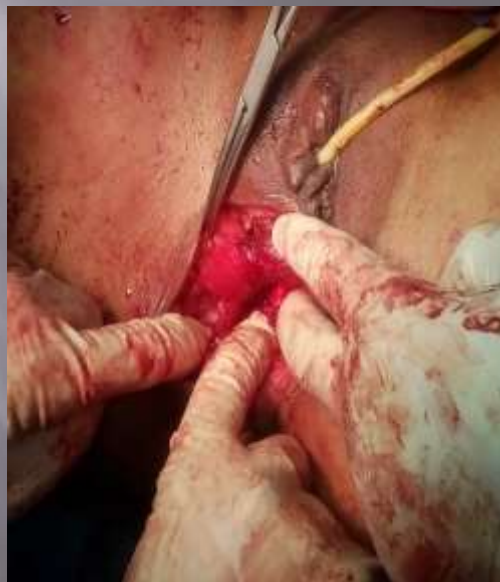Tunnelling the gracilis into the perineal wound

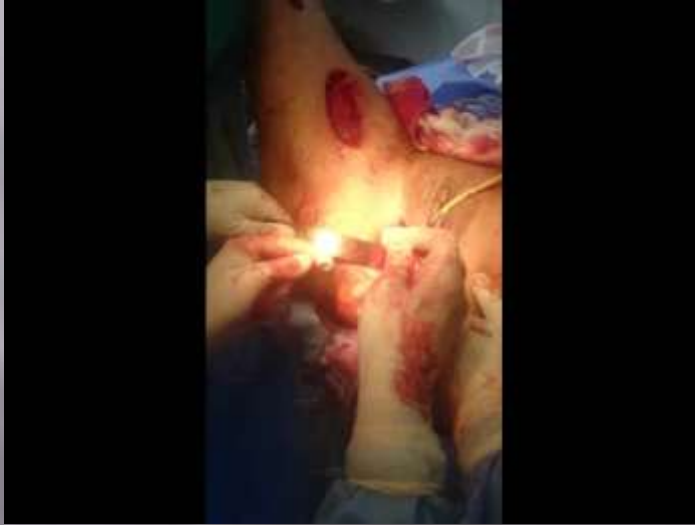

Tunnelling the gracilis into the perineal wound

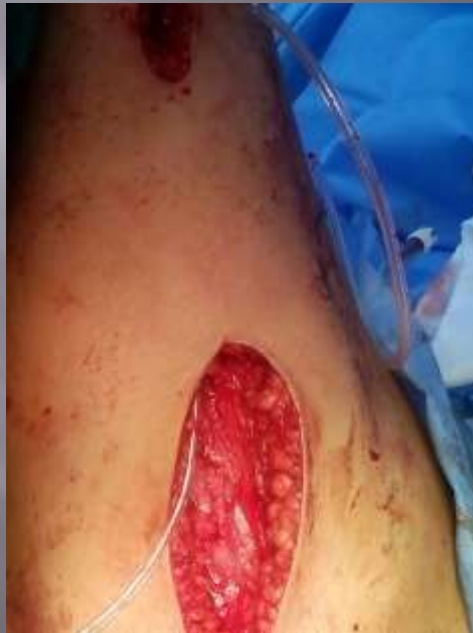

Interposition of the gracilis between the vaginal and the rectal wall

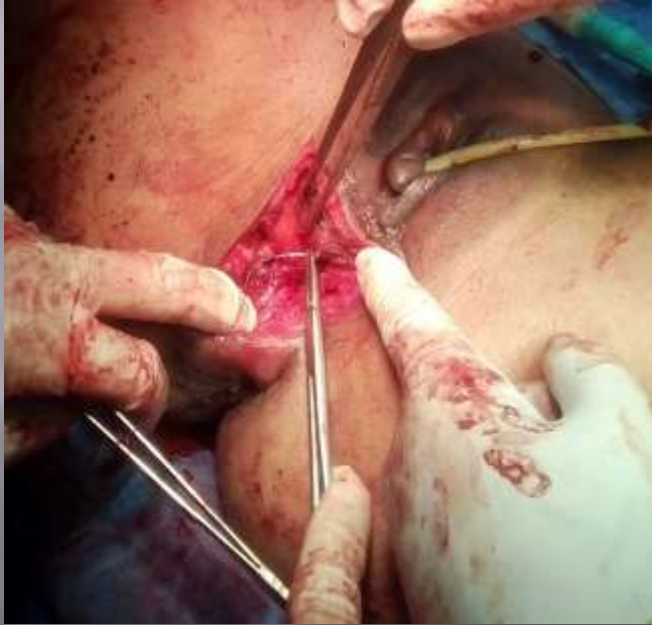



Incertion of a closed suction drain



Closure of the wounds



Closure of the wounds



