

CVL

Right colectomy



1st beyond EUROPE Masterclass

Dieter Hahnloser

dieter.hahnloser@chuv.ch

CHUV
University Hospital Lausanne
Switzerland

Concept of CME

Complete Mesocolic Excision

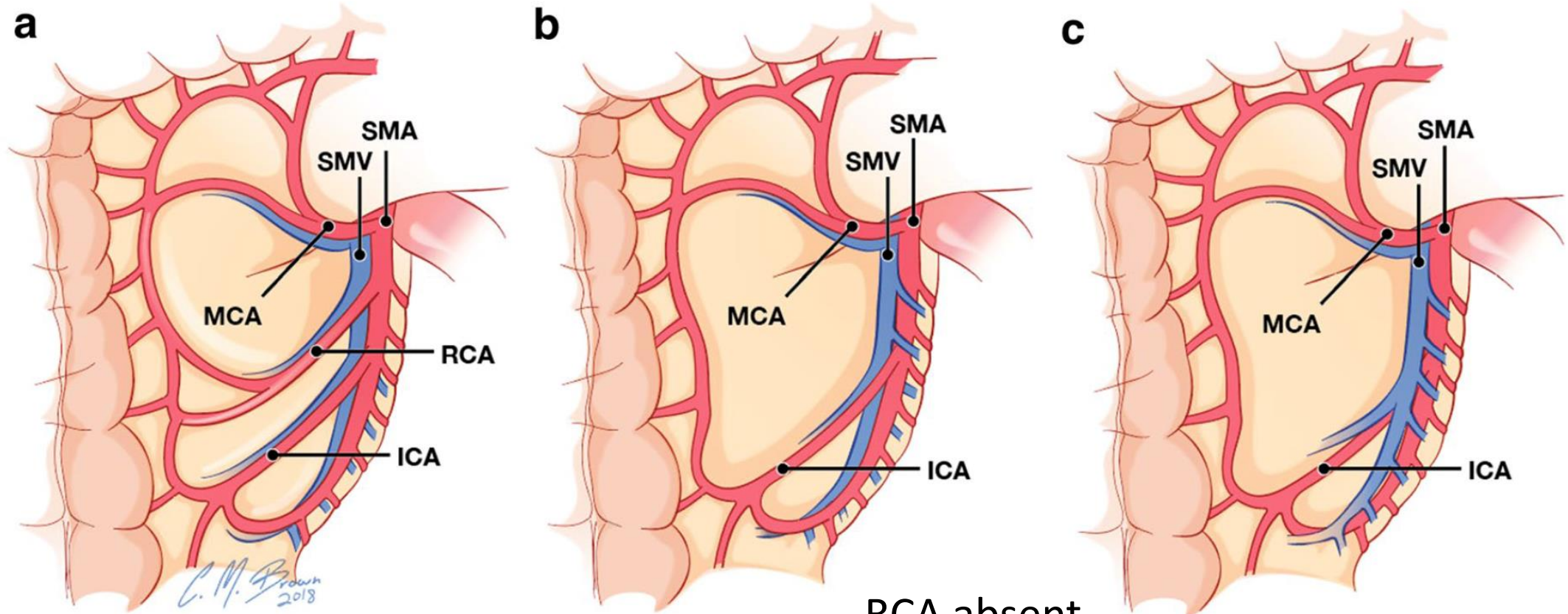
- Awareness of **parietal and mesocolic planes** with separation of both planes and leaving surfaces intact.
- Dissection of regional and central lymph nodes with **high vascular** tie of supplying arteries.
- Removal of specimen **as a „package“**.



CVL

Complete mesocolic excision and central vascular ligation for right colon cancer: an introduction for abdominal radiologists

David D. B. Bates¹ · Viktoriya Paroder¹ · Chandana Lall² · Neeraj Lalwani³ · Maria Widmar⁴ · Julio Garcia-Aguilar⁴



RCA present in 60%
(in 90% anterior SMV)

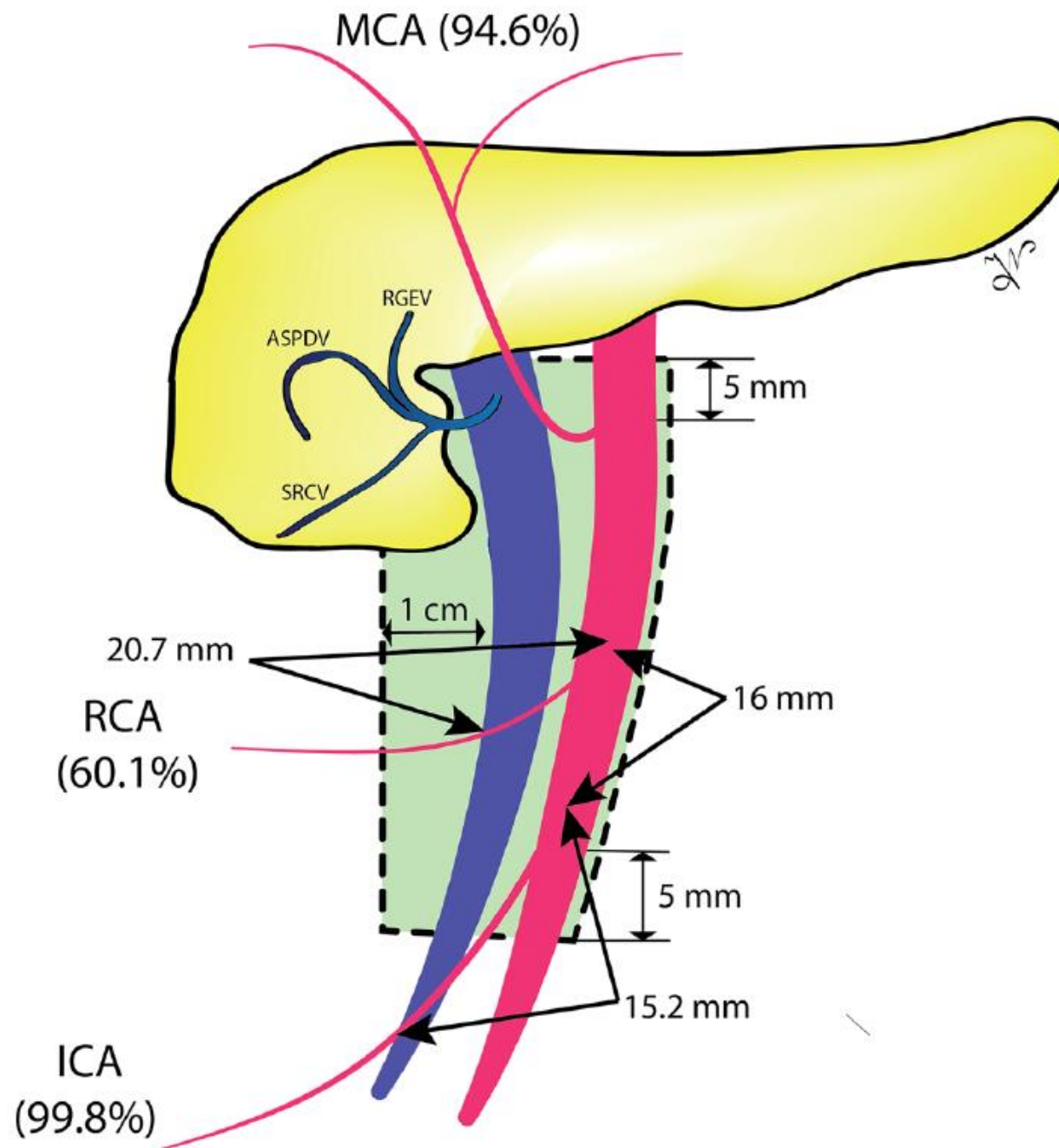
RCA absent

ICA posterior to IVC in 60%

Surgical Anatomy of the Superior Mesenteric Vessels Related to Colon and Pancreatic Surgery: A Systematic Review and Meta-Analysis

Ionut Negoii^{1,2}, Mircea Beuran^{1,2}, Sorin Hostiuc^{1,3}, Ruxandra Irina Negoii¹ & Yosuke Inoue⁴

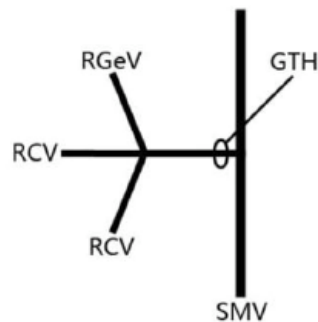
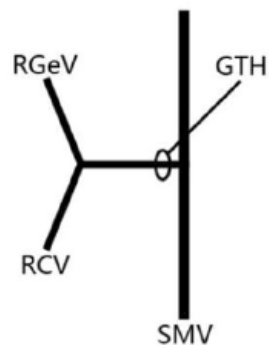
Green Area =
D3 Lymphadenectomy



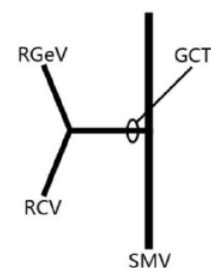
45 studies, 6090 specimens
Scientific Reports 2018

Variations in right colic vascular anatomy observed during laparoscopic right colectomy

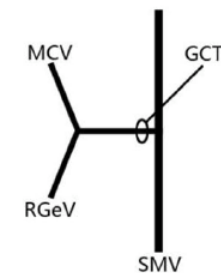
Chuying Wu[†], Kai Ye^{*†}, Yiyang Wu, Qiwei Chen, Jianhua Xu, Jianan Lin and Wengui Kang



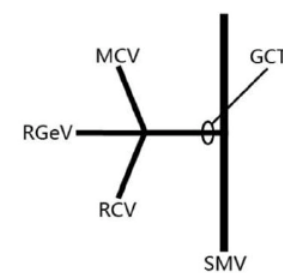
Single or double RCV draining into GTH (37/56, 66.1%)



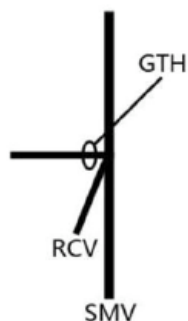
RGeV+RCV (13/53, 24.5%)



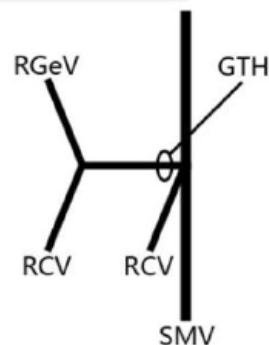
RGeV+MCV (1/53, 1.9%)



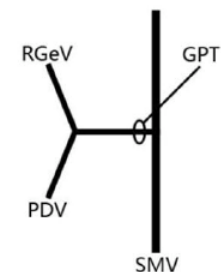
RGeV+RCV+MCV (5/53, 9.4%)



Single RCV draining into SMV (13/56, 23.2%)



One RCV draining into GTH and the other RCV draining into SMV (6/56, 10.7%)

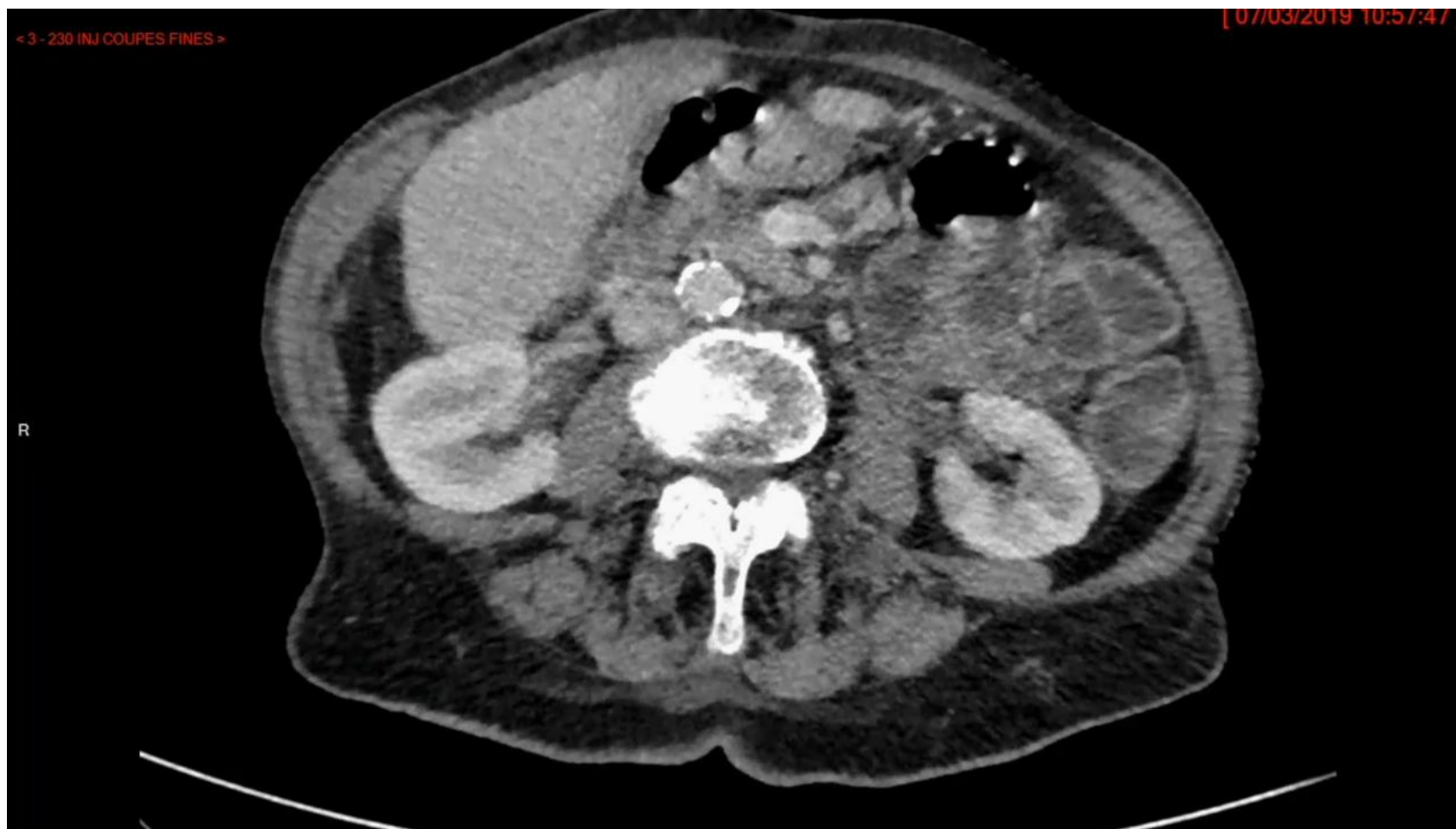

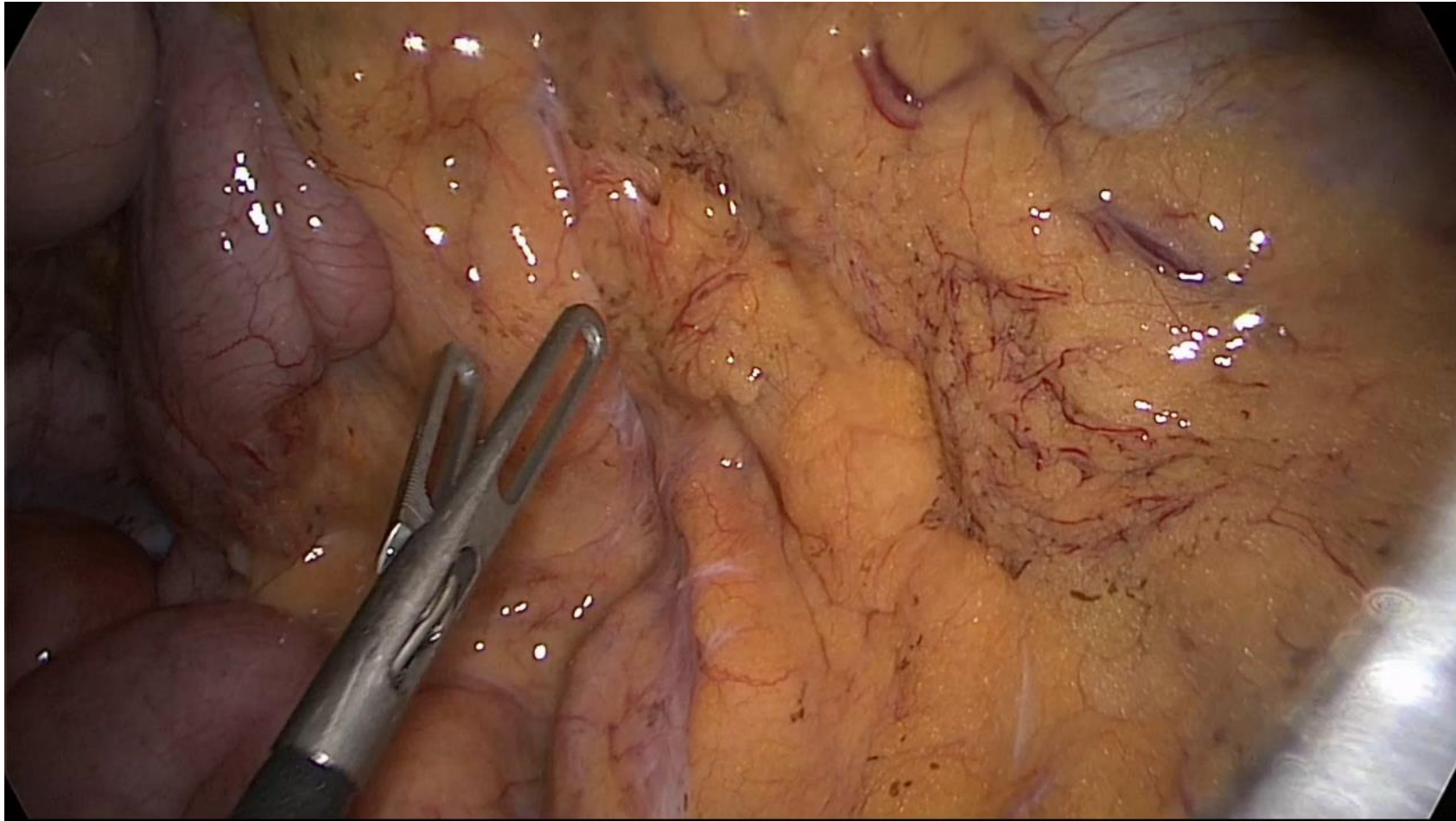
RGeV+PDV (5/53, 9.4%)

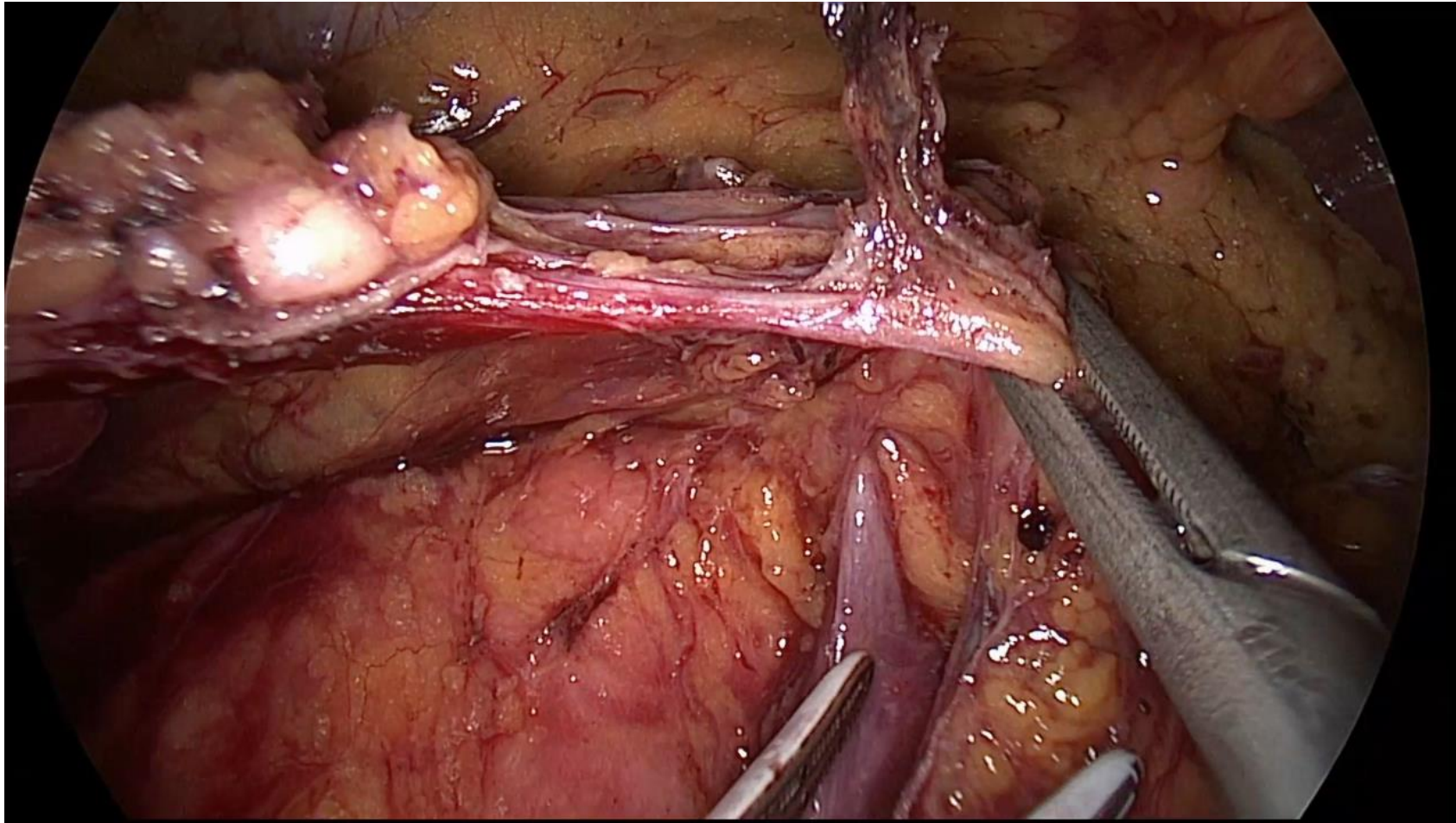
GTH: Gastrocolic Trunk of Henle

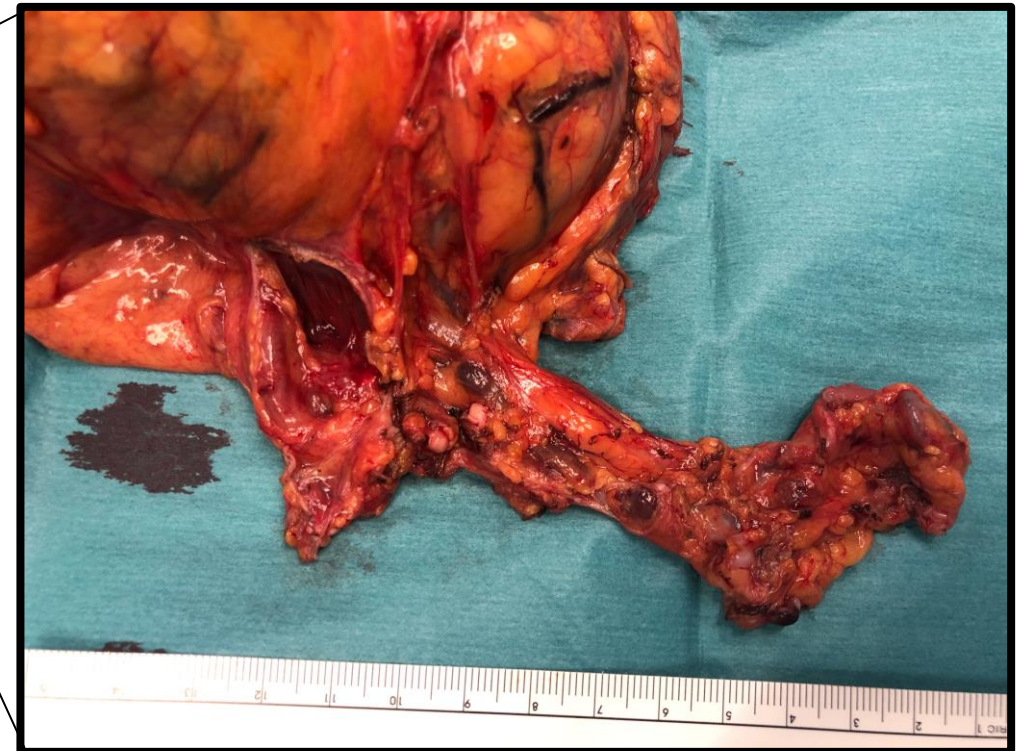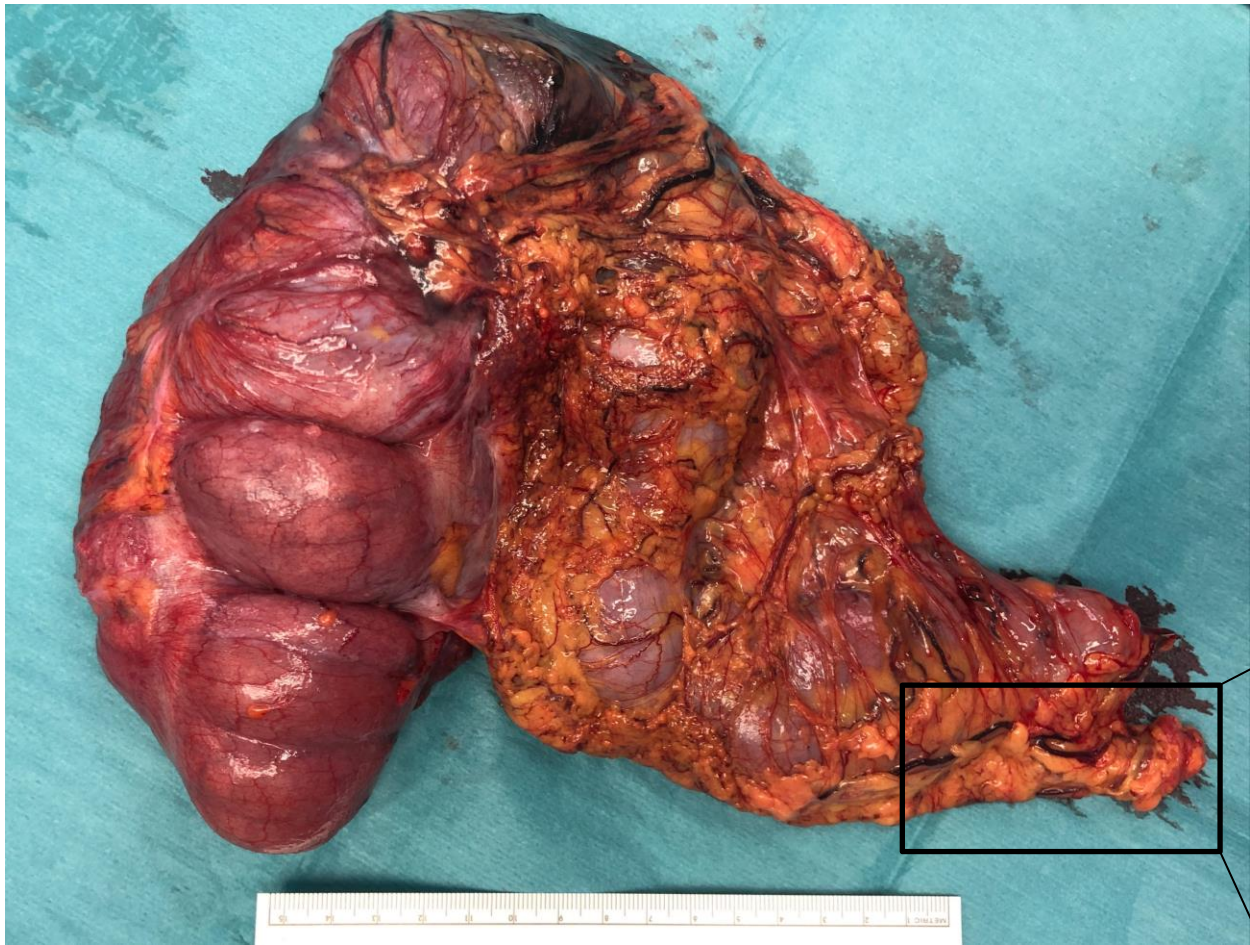
60 lap D3 R colectomies

W J Surg Oncol 2019










pT3 pN0 (0/32) cM0, L0 V0 Pn0





Video Session
State of the Art Lectures
Trial updates
Debates



22nd **ALPINE** **COLORECTAL MEETING**

26th – 28th March 2023
Courchevel, France

www.alpinecolorectal.org